

Optimizing targeted therapy for metastatic melanoma: a combination of encorafenib and trametinib beyond standard protocols

François Pélouard,¹ Valérie Chedru-Legros,² Catherine Nganoa,³ Anne Domp martin,¹ Jean-Matthieu L'Orphelin^{1,4}

¹Dermatology Department; ²Pharmacy Department; ³Nuclear Medicine Department; ⁴Interdisciplinary Research Unit for the Prevention and Treatment of Cancer, Dermatology Department, Caen University Hospital, France

Abstract

Only three combinations of BRAF inhibitor (BRAFi) and MEK inhibitor (MEKi) targeted therapies are marketed for the treatment of *BRAF*-mutated metastatic melanoma. The use of these combinations can be limited by the occurrence of severe adverse events (AEs) that may lead to discontinuation of treatment

or contraindication. We present the case of a 45-year-old male diagnosed with stage III melanoma of the left thigh, as classified by the 8th edition of the American Joint Committee on Cancer (AJCC), exhibiting rapid recurrence of inguinal lymph node metastasis following complete surgical resection. Molecular biology revealed a mutated *BRAFV600E* status, indicating treatment associated with BRAFi/MEKi. First-line treatments were introduced successively with dabrafenib-trametinib and then encorafenib-binimetinib, both stopped for fever and severe digestive AEs. After the failure of a third line with an immune checkpoint inhibitor, a new rechallenge of targeted therapy (TT) was introduced with encorafenib-trametinib to increase tolerance. This unusual and innovative combination allowed a spectacular tolerance and complete oncological response for 39 months after the failure of the usual combinations. This is the first case in the literature to show the potential efficacy of a non-standard combination of encorafenib and trametinib, which are commercialized in two different market combinations. A pharmacological evidence-based analysis was performed to understand these good clinical results.

Correspondence: François Pélouard, Dermatology Department, Caen University Hospital, 14.033 Caen, France.
E-mail: francoispelouard@gmail.com

Key words: melanoma; targeted therapy; adverse event; off-label use; drug tolerance.

Conflict of interest: JL has received consultation fees from Pierre Fabre Laboratoires, MSD, and BMS, reimbursement for meeting accommodation/travels from BMS, MSD, and Pierre-Fabre Médicaments. The remaining authors declare no conflict of interest.

Contributions: FP, data collection, analysis and interpretation, and manuscript writing; VC, CN, data collection; AD, manuscript writing; JL, study conception and design, provision of study patient, and manuscript writing. All the authors read and approved the final version of the manuscript and agreed to be accountable for all aspects of the work.

Ethics approval and consent to participate: no ethical committee approval was required for this case report by the Department because this article does not contain any studies with human participants or animals. Informed consent was obtained from the patient included in this study.

Consent for publication: written informed consent was obtained from the patient to use his personal data for the publication of this case report.

Availability of data and materials: the datasets used and/or analyzed during the current study are available from the corresponding author upon reasonable request.

Received: 4 May 2024.

Accepted: 4 February 2025.

This work is licensed under a Creative Commons Attribution-NonCommercial 4.0 International License (CC BY-NC 4.0).

©Copyright: the Author(s), 2025

Licensee PAGEPress, Italy

Dermatology Reports 2025; 17:10036

doi:10.4081/dr.2025.10036

Publisher's note: all claims expressed in this article are solely those of the authors and do not necessarily represent those of their affiliated organizations, or those of the publisher, the editors and the reviewers. Any product that may be evaluated in this article or claim that may be made by its manufacturer is not guaranteed or endorsed by the publisher.

Introduction

Prescription of BRAF inhibitor (BRAFi) agents is currently limited by marketing authorization. The value of the BRAFi *plus* MEK inhibitor (MEKi) combination in the treatment of *BRAF*-mutated metastatic melanoma has been proven since the ESMO 2019 report,¹ which highlighted the usual and commercial combinations of vemurafenib-cobimetinib,² dabrafenib-trametinib,³ and encorafenib-binimetinib,⁴ studied in the CoBRIM, COMBI-d/COMBI-v, and COLUMBUS trials, conducted by Roche, Novartis, and Pierre Fabre, respectively. Currently, only these three BRAFi/MEKi combinations have been granted marketing authorization for the treatment of *BRAFV600*-mutated metastatic melanoma. Dual therapy involves the risk of being exposed to the adverse events (AEs) of BRAFi and/or MEKi. Their combination may increase the risk of AEs but also, paradoxically, reduce the risk of some toxic dermatologic lesions when combined.^{1,5,6} Melanoma is a cancer with limited therapeutic resources, and a change of treatment line due to AEs must always be weighed up. AEs are not uncommon and may lead to temporary interruption of treatment in the case of grade III AEs or permanent discontinuation of treatment for grade IV AEs.^{1,5} They may be secondary to one molecule or the association of both. Even if there is a good carcinologic response, the targeted therapy (TT) must be switched for the other commercialized combinations when AE up to grade III occurs. We describe the first case of metastatic melanoma treated with an innovative and unusual combination of encorafenib and trametinib. A detailed pharmacological review supported the prescription used in this case report. This innovative dual therapy achieved a long-term carcinological response and spectacular tolerance after the failure of the usual combinations, which were discontinued due to grade III-IV AEs.

Case Report

A 45-year-old patient presented in September 2018 with a left thigh stage III melanoma, according to the 8th edition of the American Joint Committee on Cancer (AJCC), nodular type, Breslow thickness of 11 mm, Clark level IV, ulcerated, non-regressive, and exhibiting a high mitotic index. Initial workup with brain MRI and PET-CT revealed right inguinal adenopathy (Figure 1). The patient underwent revision surgery with 2 cm margins and a right inguinal adenectomy, confirming metastatic localization of a *BRAFV600E*-mutated melanoma. Close monitoring was performed with PET scans and brain MRI every three months until the locoregional recurrence of the right inguinal node in January 2019, treated by lymph node dissection, which detected three metastatic nodes without capsular rupture. A subsequent PET scan in February 2019 revealed a suspicious hyperfixation in the right iliac fossa, which was explored by laparoscopy in March 2019. This revealed peritoneal carcinosis which did not allow surgical excision. A new PET scan for early reassessment in April 2019 was performed and confirmed a progression of the disease with multiple metastatic lymph nodes above and below the diaphragm and nodules of peritoneal carcinosis. TT with dabrafenib-trametinib was therefore initiated in April 2019, enabling complete remission (CR) with the disappearance of iliac hyperfixation target lesions and the absence of peritoneal fixation from October 2019 to the end of January 2020 when recurrence of a right external iliac lymph node was detected and treated with local radiotherapy while continuing the same systemic treatment. In July 2020, abdominal pain (grade III) with alternating diar-

rhea/constipation and nocturnal fever (grade II) appeared, so dabrafenib-trametinib was discontinued in August 2020. A pericæcal fixation site appeared (standardized uptake value [SUV] max 2.11) on a PET scan (August 2020), which could be due to either iatrogenic inflammation with mesenteric panniculitis⁷ or local recurrence. The patient did not wish to undergo exploratory surgery, and we assumed that the fixation was due to iatrogenic inflammation and switched to encorafenib-binimetinib in September 2020. One month later, the patient presented a significant deterioration of his general condition with abdominal pain and deglobulization to 7 g/dL on an externalized gastrointestinal bleeding, with melena requiring hospitalization in intensive care. Emergency fibroscopy revealed a Forrest Ib duodenal ulcer with negative *Helicobacter pylori* samples. The patient also showed anorexia and weight loss of around 12 kg (11% of total body weight) in 6 weeks, prompting the decision to discontinue treatment. The lack of other digestive ulcer risk factors and the rapid return to baseline under symptomatic treatment alone (proton pump inhibitor), combined with discontinuation of the TT, was consistent with a grade IV AE.

Given this poor tolerability, third-line treatment with immune checkpoint inhibitors (ICI) was introduced in December 2020 and continued until July 2021 for a total of 8 cycles. Treatment was discontinued due to massive caecal progression assessed by PET scanner.

In August 2021, we rechallenged a last fourth-line treatment of TT with encorafenib-trametinib. The aim of this unusual combination was to rapidly control digestive tolerance while keeping melanoma under control.

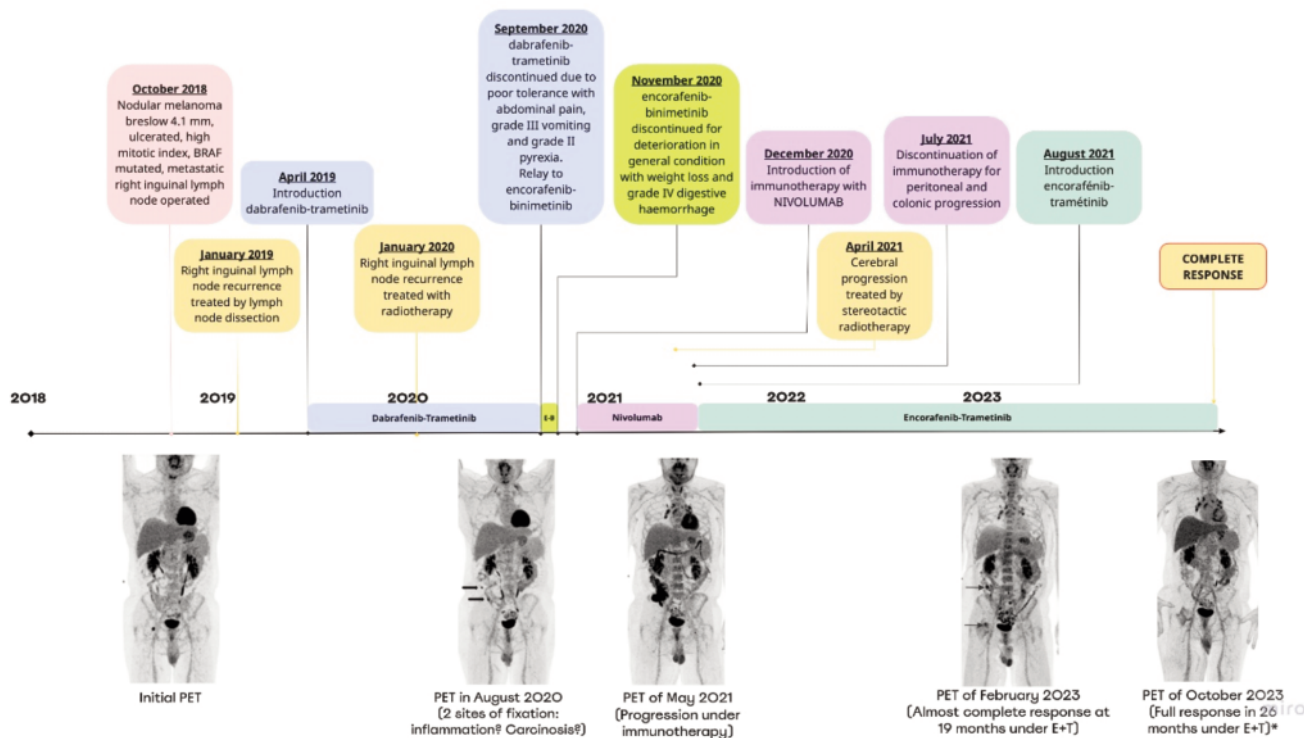


Figure 1. Timeline showing the chronological evolution of the disease. E+B, encorafenib+binimetinib; E+T, encorafenib+trametinib; *only a few perihilar lymph node hypermetabolic areas compatible with asymptomatic immune-induced sarcoidosis-like reaction remain.

This combination led to a rapid partial response as early as September 2021, followed by a complete response, notably at the caecal and peritoneal level, with the absence of any new suspicious lesion since October 2023. At the last re-evaluation in November 2024, after 39 months, the patient was still in excellent general condition, with an Eastern Cooperative Oncology Group (ECOG) performance status scale of 0, and exhibited no signs of digestive discomfort. He reports no AEs, particularly at the digestive level, under simple symptomatic treatment with trimebutine if needed. This combination has enabled the ongoing maintenance of perfect tolerance and significantly improved quality of life, as evidenced by the patient's testimonial letter in a unique manner (*Supplementary Material*). This excellent somatic tolerance enables a positive psychological impact on the disease experience.

Discussion

We report a complete carcinological response associated with an excellent safety profile in a patient treated with encorafenib-trametinib. However, these two drugs, when used in their typical combinations, had previously generated grade III-IV AEs, which justify a theoretical contraindication for their use together. This observation illustrates the fact that MEKi and BRAFi drug combinations

on the market can sometimes be modified to improve tolerance while remaining effective without changing drug class.

Gastrointestinal AEs associated with TT are not well-documented in the literature, even though they can be severe and may even lead to perforation with hemorrhagic shock, especially in the colon, primarily with encorafenib-binimetinib.⁷ In our case, the absence of any etiology for the duodenal ulcer and the rapid improvement in general condition on discontinuation of TT were strongly suggestive of a grade IV AE with encorafenib-binimetinib. We decided to rechallenge a TT because the patient had severe AEs but no carcinologic progression contrary to ICI. The encorafenib-trametinib combination seemed coherent due to the probable imputability of binimetinib in digestive hemorrhage, with bleeding events defined as very frequent in the encorafenib-binimetinib combination but not reported as frequent in patients treated with encorafenib monotherapy (see Table 5 at https://www.ema.europa.eu/en/documents/product-information/braftovi-epar-product-information_en.pdf). Trametinib was chosen because the patient did not experience any hemorrhagic events when treated with dabrafenib-trametinib, although some have been reported in the literature (see Tables 4 and 5 at https://ec.europa.eu/health/documents/community-register/2020/20200204147177/anx_147177_en.pdf). Vemurafenib and cobimetinib were not considered because these molecules are known to be less effective.¹ Therefore, the only feasible innovative combination was encorafenib-trametinib. After reviewing the phar-

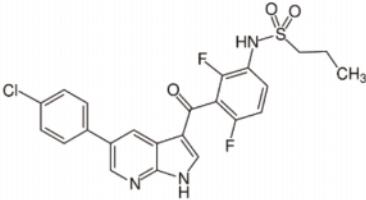
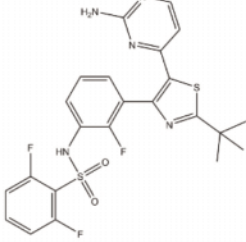
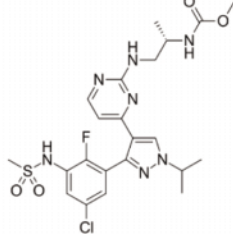
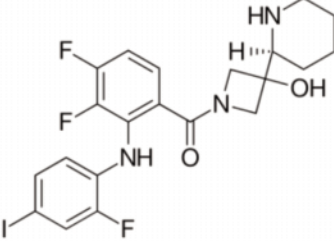
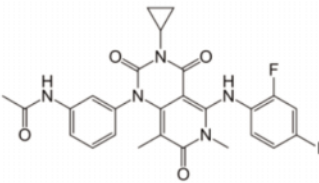
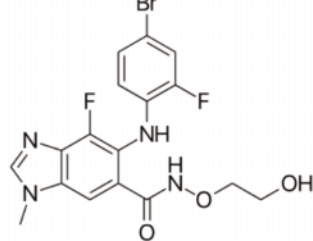
BRAF inhibitors	VEMURAFENIB	DABRAFENIB	ENCORAFENIB
Molecules			
Proprieties	RP2D : 960 mg td Food effect : none Bioavailability : 64% Dissociation half-life (T1/2) : 0,5 hours IC50 : 10 nM/L	RP2D : 150 mg td Food effect : intake 1 hour prior or 2 hour after meal Bioavailability : 85% Dissociation half-life (T1/2) : 2 hours IC50 : 0,65 nM/L	RP2D : 300 mg od Food effect : none Bioavailability : 95% Dissociation half-life (T1/2) : 30 hours IC50 : 0,35 nM/L
MEK inhibitors	COBIMETINIB	TRAMETINIB	BINIMETINIB
Molecules			
Proprieties	RP2D : 60 mg od Food effect : none Bioavailability : 46% IC50 : 4,2 nM/L	RP2D : 2 mg od Food effect : intake 1 hour prior or 2 hour after meal Bioavailability : 72% IC50 : 0,92-3,4 nM/L	RP2D : 45 mg td Food effect : none Bioavailability : 50% IC50 : 12 nM/L <i>miro</i>

Figure 2. Molecular structure and pharmacokinetic properties of BRAFi and MEKi. Adapted from Heinzerling L, Eigentler TK, Fluck M, et al. Tolerability of BRAF/MEK inhibitor combinations: adverse event evaluation and management. ESMO Open 2019;4:e000491 (Figure 1: Structural and population pharmacokinetic properties [single drug] of the BRAF indicators dabrafenib, vemurafenib and encorafenib and the MEK indicators trametinib, cobimetinib and binimetinib). RP2D, recommended phase 2 dose; IC, inhibitory concentration; od, once a day; td, twice a day.

macological data and confirming the excellent efficacy of this combination,⁸ this choice was discussed and validated in a multidisciplinary consultation meeting, given the therapeutic deadlock in this young patient. This approach, outside of standard practices, was explained and accepted by the patient by signing a consent form. Since the treatment is given out of any clinical research protocol, no ethical approval was mandatory. We did not alter the standard dosage used in the commercial combinations. This approach appeared suitable, permitting CR, which has been sustained to this day with perfect tolerance.

BRAFⁱ and MEKⁱ are recommended in other solid cancers,⁹ but no unusual combinations are recommended for these indications. A recent article studied the nine possible BRAFⁱ/MEKⁱ combinations *in vitro* by mixing the usual TT. A clear efficacy of the encorafenib-trametinib combination was reported, confirming our clinical results by demonstrating that this combination had the best pro-apoptotic activity on mutated *BRAF*-mutated cells, particularly at lower concentrations,⁸ which could also explain the better tolerability of this combination, as the toxicity of these drugs is partly dose-dependent.¹⁰ Another unusual combination of dabrafenib and cobimetinib has already been reported.¹¹ A patient was treated with dabrafenib monotherapy. Due to changes in the marketing authorization, trametinib was added as dual therapy, and the patient developed grade III fever episodes, leading to recurrent treatment interruptions. As the combination of dabrafenib and trametinib is known to be most likely to cause fever (53% of patients)³ TT was switched to an unusual combination of dabrafenib-cobimetinib, resulting in improved tolerance and complete response for 19 months. The frequency of AEs varies according to the combinations used,¹ and it may be useful to guide the choice of the combination according to the type of AE that needs to be avoided. To understand how AEs occur, we must consider the pharmacological and genetic differences that depend on molecules and patients (Figure 2). Other factors, like drug interactions and the tumor microenvironment, can also influence pharmacokinetic and pharmacodynamic parameters. Simple pharmacological markers, such as receptor dissociation half-life or bioavailability, demonstrate that encorafenib and trametinib are BRAFⁱ/MEKⁱ molecules that exert rapid and prolonged effects on their target receptors.^{1,12} The inhibitory concentration 50 (IC₅₀) also results in greater antitumor activity at smaller doses, which may limit AEs if we consider them to be dose-dependent.^{1,10} Nevertheless, these parameters cannot be directly correlated with the efficacy and tolerability of these treatments. The pathophysiological study of cutaneous AEs from BRAFⁱ monotherapy has revealed the superiority of dual BRAFⁱ and MEKⁱ therapy.¹³ However, no study has been able to explain the differences in tolerance of these combinations. The tolerance of each combination differs from patient to patient, without any pharmacological or physiopathologic explanation. Investigating these mechanisms may enhance our comprehension of the disparities in AE profiles and facilitate the customization of prescriptions for individual patients, as well as enable transitions between BRAFⁱ-MEKⁱ combinations when AEs arise.

Conclusions

Beyond commercial constraints, unusual BRAFⁱ/MEKⁱ combinations could offer a personalized alternative that is more aligned

with patients' specific needs according to the tolerance profile offered by each molecule. However, the decision to introduce off-label treatments is not recommended and should be discussed on a case-by-case basis, under the control of multidisciplinary decisions, when standard treatments fail or when toxicity compromises their effectiveness. Ideally, clinical trials and phase IV studies should be established to better assess the impact of these treatments in terms of oncological responses and safety profiles. These data could contribute to obtaining new marketing authorizations and practical recommendations, allowing clinicians to better define these combinations' role in addressing therapeutic deadlock situations.

References

1. Heinzerling L, Eigentler T, Fluck M, et al. Tolerability of BRAF/MEK inhibitor combinations: adverse event evaluation and management ESMO Open 2019;4:e000491.
2. Larkin J, Ascierto PA, Dréno B, et al. Combined Vemurafenib and Cobimetinib in BRAF-Mutated Melanoma. *N Engl J Med* 2014;371:1867-76.
3. Robert C, Karaszewska B, Schachter J, et al. Improved Overall Survival in Melanoma with Combined Dabrafenib and Trametinib. *N Engl J Med* 2015;372:30-9.
4. Dummer R, Ascierto PA, Gogas HJ, et al. Overall survival in patients with BRAF-mutant melanoma receiving encorafenib plus binimetinib versus vemurafenib or encorafenib (COLUMBUS): a multicentre, open-label, randomised, phase 3 trial. *Lancet Oncol* 2018;19:1315-27.
5. Sibaud V, Baric L, Cantagrel A, et al. Gestion des toxicités des inhibiteurs BRAF et MEK dans le mélanome métastatique. *Bull Cancer* 2021;108:528-43.
6. Abdel-Rahman O, ElHalawani H, Ahmed H. Doublet BRAF/MEK inhibition versus single-agent BRAF inhibition in the management of BRAF-mutant advanced melanoma, biological rationale and meta-analysis of published data. *Clin Transl Oncol* 2016;18:848-58.
7. Carbonnel F, Routier E, Lazure T, et al. Severe colitis in patients with melanoma treated with BRAF/MEK inhibitors. *Aliment Pharmacol Ther* 2023;57:792-9.
8. Schulz AL, Raetz J, Karitzky PC, et al. Head-to-Head Comparison of BRAF/MEK Inhibitor Combinations Proposes Superiority of Encorafenib Plus Trametinib in Melanoma. *Cancers* 2022;14:4930.
9. Gouda MA, Subbiah V. Precision oncology for BRAF-mutant cancers with BRAF and MEK inhibitors: from melanoma to tissue-agnostic therapy. *ESMO Open* 2023;8:100788.
10. Delord JP, Robert C, Nyakas M, et al. Phase I dose-escalation and -expansion study of the BRAF inhibitor encorafenib (LGX818) in metastatic BRAF-mutant melanoma. *Clin Cancer Res* 2017;23:5339-48.
11. Leenhardt F, Mbatchi L, Evrard A, et al. Unusual association of BRAF and MEK inhibitors: Clinical response of metastatic melanoma treated with dabrafenib-cobimetinib. *Bull Cancer* 2023.
12. Smith DA, Beaumont K, Maurer TS, Di L. Relevance of Half-Life in Drug Design. *J Med Chem* 2018;61:4273-82.
13. Adelman CH, Ching G, Du L, et al. Comparative profiles of BRAF inhibitors: The paradox index as a predictor of clinical toxicity. *Oncotarget* 2016;7:30453-60.

Online Supplementary Material:

Testimonial letter: The letter describes the experience of illness from the patient's point of view.