

The suitability of mesenchymal stem cells for treating immune-mediated inflammatory skin diseases: a systematic review

Elena Pezzolo,^{1,2} Sara Di Leo,^{1,2} Paola Miceli,¹ Alvisè Sernicola,³ Luigi Naldi^{1,2}

¹Department of Dermatology, San Bortolo Hospital, Vicenza; ²Study Centre of the Italian Group for the Epidemiologic Research in Dermatology, Bergamo; ³Dermatology Unit, Department of Medicine, University of Padua, Italy

Abstract

Mesenchymal stem cell (MSC) therapy holds promise for treating immune-mediated inflammatory skin diseases (IMIDs), particularly when conventional therapies are ineffective. Encouraged by their immunomodulatory capabilities and potential for disease modification, different clinical trials are investigating the efficacy and safety of MSCs in single IMIDs. This review aims to summarize the application of MSCs in IMIDs and explore their future clinical potential. We reviewed published studies from January 2016 to January 2024 on MSC treatment for IMIDs. We retrieved 18 clinical trials and 5 observational studies, encompassing 609 patients with psoriasis, atopic dermatitis (AD), chronic spontaneous urticaria (CSU), alopecia areata (AA), systemic sclerosis (SSc), and systemic lupus erythematosus (SLE). Improvements or complete remission were observed in up to 100% of cases for AA, SSc, and SLE, though complete remission rates were less frequent than improvement rates, ranging from 0% in AD to 50% in CSU. Adverse events (AEs) were generally mild; moderate-severe AEs were uncommon (4% in psoriasis, 2.6% in SLE, and 0.7% in SSc), and deaths from all causes were rare (6 patients with SSc and 15 patients with SLE). In conclusion, MSC therapy shows promising results in terms of at least partial clinical improvement for most IMIDs. Its effect is achievable after a single or a few administrations, with no significant toxicity. MSCs may fulfill an unmet need for patients unresponsive to conventional immunomodulating agents. However, most evidence still comes from clinical trials with heterogeneous designs and endpoints. Future larger controlled trials are needed to better elucidate their role in refractory IMIDs.

Key words: atopic dermatitis; immune-mediated inflammatory skin diseases; mesenchymal stem cells; psoriasis; urticaria.

Correspondence: Elena Pezzolo, Department of Dermatology, San Bortolo Hospital, Vicenza, Viale Rodolfi 37, 36100 Vicenza, Italy.
Tel.: +39044475-7130/7872. Fax: +390444753809. E-mail: elena.pezzolo@aulss8.veneto.it

Introduction

Mesenchymal stem cell (MSC) therapy utilizes MSCs, which are multipotent stromal cells with self-renewal and differentiation capabilities, for therapeutic purposes. MSCs are isolated from tissues, expanded, and then administered to patients to exert tissue repair, immune modulation, and other therapeutic effects. They are among the most studied stem cells due to their unique characteristics of self-renewal and the potential to differentiate into multiple cell types.¹ Their use offers ethical advantages compared to other stem cells due to their non-controversial sources, lower risk of tumor formation, reduced immunogenicity, clear consent processes, and broad acceptance in the medical and regulatory communities.²

Mechanisms of MSC therapy

MSCs possess anti-inflammatory and regenerative properties through transforming growth factor (TGF)- β , interleukin (IL)-10, and indoleamine 2,3-dioxygenase (IDO).³ They promote angiogenesis *via* vascular endothelial growth factor and basic fibroblast growth factor, aiding wound healing.⁴ MSCs can differentiate into keratinocytes and fibroblasts, supporting skin regeneration and remodeling.⁵ Their immunomodulatory effects *in vitro* include

inhibiting T-cell proliferation and natural killer cell activity, altering hematopoietic stem cell (HSC) and monocyte differentiation, and reducing dendritic cell antigen presentation, as well as effects on B-cell proliferation and signaling. In psoriasis, MSCs may induce a regulatory/immunosuppressive phenotype in T helper (Th)17 cells by modulating interferon (IFN)- γ and tumor necrosis factor (TNF) pathways.⁶

Source, administration routes, and effective dose of MSCs

Various MSC sources exist, including bone marrow, adipose tissue, and umbilical cord tissue, each with unique benefits for accessibility and proliferative capacity.⁷ For example, adipose-derived MSCs (AD-MSCs) are favored for their easy acquisition, abundance in fat, and immunomodulatory role in conditions such as psoriasis. Administration routes, such as local injection, topical application, and systemic infusion, are chosen based on the target tissue for specific delivery benefits.⁸ The optimal MSC dosage is still being studied, with research testing cell concentrations from thousands to millions per administration, often tailored to the condition's severity and therapeutic goals.⁷

Potential risks of MSCs

Autologous MSCs avoid the safety concerns linked to immunoablation and allogeneic transplantation in HSC transplantation (HSCT). However, one concern with MSCs is the possibility of ectopic tissue formation, wherein MSCs differentiate into unintended cell types or cause aberrant tissue growth. MSC-induced immunomodulation could worsen certain autoimmune conditions or aid immune evasion in cancerous tissues.⁹ Additional risks stem from contamination during cell isolation and expansion, and adverse events (AEs) to culture media or cryoprotectants.¹⁰ Clinical-grade MSC production demands strictly controlled environments to prevent contamination and genetic instability, ensuring product safety and consistency. These cell factories must adhere to stringent Food and Drug Administration and European Medicines Agency guidelines, covering donor selection and cell manipulation, to standardize and integrate these advanced therapeutics in clinical practice.¹¹

Therapeutic potential of MSCs in immune-mediated inflammatory skin diseases

MSC therapy in dermatology began as a concept of cell replacement therapy for skin defects and wound healing.⁶ Immunomodulatory capabilities suggest potential for treating chronic immune-mediated inflammatory skin diseases (IMIDs),^{2,12-16} especially in patients unresponsive to conventional therapy. Positive effects have been seen in preclinical models of psoriasis, atopic dermatitis (AD), chronic spontaneous urticaria (CSU), alopecia areata (AA), systemic sclerosis (SSc), and systemic lupus erythematosus (SLE). Encouraged by these results, different clinical trials are investigating the efficacy and safety of MSCs in these diseases.¹⁷ This review aims to summarize the current therapeutic application of MSCs in IMIDs and explore their future clinical potential.

Materials and Methods

A literature search was performed using PubMed, Embase, MEDLINE, and the Cochrane Central Register of Controlled Trials for studies on IMID treatments with MSCs published from January 2016 to January 2024. Search terms included: psoriasis OR atopic OR prurigo* OR urticaria OR alopecia OR scleroderma* OR lupus AND mesenchymal cell*. PubMed searches were limited to: i) using MSCs; ii) using MSCs as advanced therapy for skin conditions; iii) in humans; and iv) written in English. Reviews, guidelines, protocols, and commentaries were excluded. Duplicates were also removed.

Two authors (EP and SDL) independently screened study titles and abstracts against the inclusion and exclusion criteria and examined full texts of potentially relevant studies. Rejected studies were recorded with reasons; case reports were also excluded. A third author (PM) resolved any selection disagreements. The Preferred Reporting Items for Systematic reviews and Meta-Analyses (PRISMA) flowchart details search results and reasons for study exclusions (Figure 1). Four authors (EP, PM, SDL, and AS) manually extracted data from included studies, focusing on study design, patients number, MSCs source, administration route, cells dose and schedule, outcomes, follow-up duration, and patient and disease characteristics, such as diagnosis, sex, age, disease duration, skin involvement, previous treatments, MSCs response, and AEs (Tables 1 and 2).

Results

Eighteen clinical trials and five observational studies have evaluated MSC therapy for IMIDs (Figure 1), involving 609 patients: 282 with SLE, 216 with SSc, 39 with AD, 38 with AA, 24 with psoriasis, and 10 with CSU. The preferred method was intravenous (IV) administration of allogeneic MSCs (12/23 studies). Other routes of delivery included direct injection (3/23 studies), implantation (1/23 studies), subcutaneous administration (5/23 studies), and topical application (2/23 studies). MSCs were derived from human umbilical cord blood (10/23 studies), bone marrow (8/23 studies), and adipose tissue (9/23 studies) (Table 1).

Clinical benefits (improvement or complete remission) were observed with the following rates: up to 100% for SLE, SSc, and AA; 50% for AD; 54.2% for psoriasis; and 80% for CSU. Complete remission varied from 0% in AD to 50% in CSU. The time to improvement ranged from 1 to 16 months, with remission lasting 1 to 22 months, depending on the study follow-up length.

AEs were common but mostly mild, with the highest occurrence in psoriasis (95.8%), primarily including skin reactions, gastrointestinal symptoms, and respiratory infections. Mild AEs were also reported in 57.9% of AA patients, 39.4% of AD patients, 29.9% of SSc patients, and 21.9% of SLE patients. Moderate-to-severe AEs were rare, occurring in 4.2% of psoriasis patients, 2.6% of SLE patients, and 0.7% of SSc patients. No AEs were reported in patients with AD, CSU, or AA. Deaths from all causes were very rare, being 6 in SSc patients and 15 in SLE patients (Table 2).

Psoriasis

An open-label pilot study by Yao *et al.* investigated AD-MSCs for psoriasis treatment in 7 patients aged 35-65 years.¹⁸ Monthly IV AD-MSC injections (0.5×10^6 cells/kg) for 12 weeks led to a gradual decrease in Psoriasis Area and Severity Index (PASI), with 2 patients maintaining PASI-50 at 6 months.¹⁹ In another open-label trial, Cheng *et al.* treated 17 psoriasis patients aged 18-65 years with umbilical cord-derived MSCs (UC-MSC) infusions. At 6 months, 47.1% showed at least 40% improvement, 35.3% had at

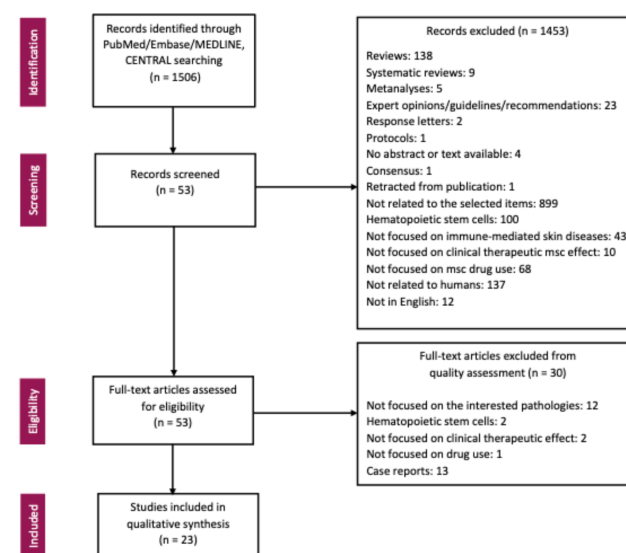


Figure 1. Flow diagram summarizing the selection of relevant studies according to the PRISMA statement.

Table 1. Clinical studies assessing mesenchymal stem cells for the treatment of immune-mediated inflammatory skin disorders.

Skin disease	Author, year	Study design	Number of cases	MSC source	Associated standard therapies	Route	Cell dose	Administration, n; frequency	Outcome (% pts), follow-up
PSO	Yao <i>et al.</i> , 2021	Open-label trial	7	AD-MSCs	No	IV	0.5×10 ⁶ /kg	3; w 0, 4, 8	PASI-50 (28%), 6 months
	Cheng <i>et al.</i> , 2022	Ph I/IIa open-label trial	17	UC-MSCs	No	IV	1.5/2.2, 2.5/3×10 ⁶ /kg	I: 4; q2w/IIa: 4; q2w & 2; q4w	PASI-75 (35%), PASI-90 (18%), 6 months
AD	Kim <i>et al.</i> , 2017	Ph I/IIa open-label trials	34	AI UC-MSCs	No	SC	2.5×10 ⁷ or 5×10 ⁷	I	EASI-50 (55%), EASI-75 (27%), 3 months (high dose)
	Shin <i>et al.</i> , 2021	Open-label trial	5	AI BM-MSCs	No	IV	1.0×10 ⁶ /kg	3×2 cycles; q2wk	EASI-50 after 1st-2nd cycle (80%), 1-2 months
CSU	Özdemir <i>et al.</i> , 2021	Open-label CT	10	Au AD-MSCs	Doubt omalizumab	IV	1×10 ⁶ /kg	2; d 0, 14	UAS75 (50%), 3 months; ≤UAS75≤6 (30%), 6 months
AA	Elmadawi <i>et al.</i> , 2018	RCT	20	Au BM-MSCs/FSC	No	ID	1×10 ⁶ /mL	I	Improvement (100%), 1-6 months
	Czamecka <i>et al.</i> , 2021	Open-label trial	4	AI UC-MSCs	No	SC	5×10 ⁶ /mL	I	Hair growth by 67% (100%), 3 months
	Lee <i>et al.</i> , 2022	Retrospective	14	AD-MSCs	No	Top	NA	Ph 1: 15; Pt 2: 20; Pt 3: 20; NA	Hair growth >50% (64%); remission (43%), 3-8 months
SSc	Zhang <i>et al.</i> , 2017	Ph I/II open-label trial	14	AI UC-MSCs	CYC	IV	1×10 ⁶ /kg	I	Reduction MRSS (100%), 3 months
	Blezien <i>et al.</i> , 2017	Open-label trial	7	Au AD-MSCs	No	I	NA	I	Reduction microstomia/microcheilia (100%), 6-12 months
	Virzi <i>et al.</i> , 2017	Open-label CT	6	Au AD-MSCs	No	I	NA	I	Improvement oral/malar skin elasticity (100%), 3 months
	Liang <i>et al.</i> , 2018	Retrospective	39	AI UC/BM-MSCs	CS, CYC, MTX, LEF, MMF, FK506, HCQ	IV	1×10 ⁶ /kg	I	NA
	Almadori <i>et al.</i> , 2019	Open-label trial	62	Au AD-MSCs	50% MMF, MTX, 50% No	I	NA	Mean 3; NA	Improvement MHISS (100%), 6 months
	Shoji <i>et al.</i> , 2019	Retrospective	39	Au BM-MSCs	CS; immunosuppressants	Impl	4.20×10 ⁶ /kg	I	Improvement rest pain VAS (100%), 6 months
	Del Papa <i>et al.</i> , 2019	Controlled trial	25	Au AD-MSCs	No	SC	0.5-1 mL/finger	I	Healing IDU (97%), 2 months
	Park <i>et al.</i> , 2020	Ph I open-label trial	18	Au AD-MSCs	No	SC	3.61×10 ⁶ /finger	I	Reduction MRSS (100%), 2 weeks
	Wang <i>et al.</i> , 2021	RCT	6	Au AD-MSCs	No	SC	5×10 ⁶ /mL	I	Improvement facial atrophy, 6 months
	Wang <i>et al.</i> , 2016	Open-label trial	9	AI UC-MSCs	No	IV	1×10 ⁶ /kg	2; d 0, 7	Remission (22%); improvement BILAG (56%), NA
SLE	Wang <i>et al.</i> , 2017	Ph I/II open-label trial	17	AI UC-MSCs	No	IV	NA	NA	Improvement BILAG (65%), 12 months
	Liang <i>et al.</i> , 2018	Retrospective	178	AI UC/BM-MSCs	CS, CYC, MTX, LEF, MMF, FK506, HCQ	IV	1×10 ⁶ /kg	I	Major (32.5%); partial (27.5%) remission, 12 months
	Barbado <i>et al.</i> , 2018	Open-label trial	3	AI BM-MSCs	No	IV	1.5×10 ⁶ /kg	I	Remission (66%); improved SLEDAI (33%), 1-9 months
	Wen <i>et al.</i> , 2019	Retrospective	69	AI UC/BM-MSCs	No	IV	1×10 ⁶ /kg	1 or 2; d 0, 30	Remission (23%); improvement SLEDAI (58%), 12 months
	Kamen <i>et al.</i> , 2022	Ph I open-label trial	6	AI UC/BM-MSCs	CS, CYC, HCQ, MMF, AZA, CSA	IV	1×10 ⁶ /kg	I	Improvement SRI (83.3%), 6 months

AA, alopecia areata; AD, atopic dermatitis; AD-MSCs, adipose tissue-derived mesenchymal stem cells; AI, allogeneic; Au, autologous; AZA, azathioprine; BEBSS, Birmingham Epidemiology Bullosa Severity Score; BILAG, British Isles Lupus Assessment Group Score; BM-MSCs, bone marrow-derived mesenchymal stem cells; BSA, body surface area; CM-MSCs, mesenchymal stem cell conditioned media; CS, corticosteroids; CSA, cyclosporin A; CSU, chronic spontaneous urticaria; CT, control trial; CYC, cyclophosphamide; d, day; EsSG, European Scleroderma Study Group; FK506, tacrolimus; FSC, follicular stem cells; G-MSCs, human gingiva-derived mesenchymal stem cells; HCQ, hydroxychloroquine; I, injective; ID, intradermal; IDU, ischemic digital ulcer; Impl, implantation; IV, Intravenous; LEF, leflunomide; MHISS, mouth handicap in systemic sclerosis scale; MMF, mycophenolate mofetil; MRSS, Modified Rodnan Skin Score; MTX, methotrexate; NA, not available; Od, once daily; PASI, Psoriasis Area Severity Index; ph, phase; PSO, psoriasis; PSSI, Psoriasis Scalp Severity Index; Pt, patient; QoL, Quality of Life; SRI, SLE Responder Index; q2wk, once every two weeks; qw, once a week; RCT, randomized control trial; SC, subcutaneously; SLE, systemic lupus erythematosus; SSc, systemic sclerosis; Top, topical; UAS7, Urticaria Activity Score over 7 Days; UC-MSCs, umbilical cord-derived mesenchymal stem cells; ys, years.

least 75% improvement, and 17.6% had over 90% improvement in PASI. Among those with PASI-75 improvement, only one patient had sustained benefits.

Both studies found IV MSCs infusions safe and partially effective for psoriasis, suggesting promising efficacy and tolerability.

Atopic dermatitis

Two clinical trials have shown the benefits of MSCs in treating AD.^{20,21} In a phase I/IIa trial, 34 adults with moderate-to-severe AD received subcutaneous injections of low-dose (2.5×10^7) or high-dose (5×10^7) UC-MSCs every two weeks for 12 weeks.²⁰ Symptom improvement was dose-dependent, with 55% of the high-dose group achieving Eczema Area and Severity Index (EASI) 50 with mild AEs, such as skin infections and gastrointestinal issues in 56% of the group. The high-dose group also saw reductions of 33% in Investigator Global Assessment (IGA), 50% in scoring AD (SCORAD), and 58% in pruritus, as well as reduced serum IgE levels and blood eosinophil counts.

In another clinical trial, five adults with moderate-to-severe AD refractory to conventional therapy received IV injections of allogeneic bone marrow-derived MSCs (BM-MSCs) (1.0×10^6 cells/kg) three times every two weeks.²¹ This led to significant improvements in EASI, SCORAD, body surface area, and IGA by week 16, with 80% achieving EASI-50 after one or two cycles. No serious AEs were observed over 38 weeks. Cytokines CCL-17, IL-13, and IL-22 decreased, while IL-17 increased in patients with a good response over 84 weeks.

These studies highlight the clinical usefulness of MSC therapy in patients unresponsive to conventional therapies. However, further studies with larger sample sizes and rigorous experimental designs are needed to better define MSC therapy's potential in AD.

Chronic spontaneous urticaria

A clinical study investigated the use of MSCs in patients with CSU resistant to conventional therapies, including omalizumab.²² Ten patients with CSU for at least 12 months received autologous AD-MSCs intravenously at baseline and after two weeks. Five patients showed a persistent complete response up to 6 months, three had well-controlled CSU, and two experienced no improvement. MSC therapy provided a longer and more effective recovery compared to conventional treatments. Compared to control groups, MSC therapy did not affect CD4⁺ T cell subsets and serum levels of various cytokines and inflammatory markers, such as IFN- γ , TNF- α , IL-2, IL-4, IL-5, IL-6, IL-10, IL-13, IL-17a, IL-21, IL-22, TGF- β 1, prostaglandin E2 (PGE2), IDO, and anti-Fc ϵ RI, during follow-up. In contrast, control patients showed significant decreases in Th2 cells, TGF- β 1, PGE2, IDO, and anti-Fc ϵ RI by day 14.

This study suggests that MSCs might offer a promising alternative for CSU patients resistant to current therapies such as omalizumab, potentially modifying disease progression.

Alopecia areata

Preclinical and case studies have explored the use of MSCs in treating AA.²³⁻²⁵ In a 2018 controlled trial, Elmaadawi *et al.* treated 20 patients with AA who were unresponsive to conventional therapies and had been untreated for 6 months.²³ Patients received a single intradermal injection of either autologous BM-MSCs or autologous follicular stem cells cultured from unaffected scalp areas. Clinical improvement was observed in 50% of patients in both groups without AEs. However, 45% experienced AA recurrence after a year.

In 2021, Czarnecka *et al.* administered a single intradermal

injection of allogeneic UC-MSCs (5×10^6 cells/mL) from Wharton's jelly to four AA patients resistant to conventional treatments.²⁴ The group, consisting of patients aged 36 to 57 years with AA durations of 2 to 9 years, showed an average hair regrowth of 67% in treated areas. The most significant regrowth occurred within the first 3 months (52.2%), slowing to 32% in the following 3 months. No AEs were reported.

A 2022 retrospective study by Lee *et al.* examined 14 patients with refractory AA patches treated with commercially available AD-MSC conditioned media, combined with either a carbon dioxide fractional laser or microneedling.²⁵ Patients, averaging 35.5 years in age and 32 months in AA duration, showed that 64.3% experienced over 50% hair regrowth, and 42.9% achieved complete recovery. Responders took an average of 11.3 weeks to achieve significant regrowth. Among non-responders, 28.6% showed less than 25% regrowth, with slight improvement in one patient after 3 months.

Managing AA is challenging for lesions resistant to conventional treatments, such as corticosteroids, contact immunotherapy, and systemic therapy. These studies show that MSCs, through their influence on the Janus kinase/signal transducers and activators of transcription signaling and Wnt/ β -catenin pathways, may offer potential clinical improvement or complete remission in up to 100% of these patients.

Systemic sclerosis

Over the past 8 years, 9 clinical studies reported the use of MSCs to treat SSc. In 2017, Zhang *et al.* treated 14 patients with diffuse cutaneous SSc using repeated plasmapheresis and cyclophosphamide, followed by a single infusion of UC-MSCs. Significant improvement in the skin involvement, assessed as a variation of the Modified Rodnan Skin Score (MRSS) from 20.1 ± 3.1 to 13.8 ± 10.2 , was observed at 1-year follow-up, with notable improvements in lung function and some patients experiencing better dysphagia and skin ulcer healing. No serious AEs occurred, though some patients experienced upper respiratory tract infections and diarrhea.²⁶

Blezien *et al.* conducted an open-label study in 2017 on 7 patients with SSc, using autologous AD-MSCs and platelet-rich plasma (PRP) for lip treatments. After 12 months, vertical and lateral oral openings improved by 15.38% and 3.97%, respectively, with significant increases in lip thickness.²⁷

In 2017, Virzi *et al.* treated 6 patients with cutaneous SSc using autologous AD-MSCs and PRP in the perioral area. After 3 months, patients showed improvements in facial morpho-functional parameters, labial rhyming opening and extension, and skin elasticity.²⁸

Liang *et al.* reviewed 39 SSc patients who received IV infusions of allogeneic BM-MSCs and UC-MSCs in 2018. Seven patients experienced hyperacute AEs, including headache, fever, and stomach pain, and 6 patients died.²⁹

An open-label trial by Almadori *et al.* in 2019 treated 62 SSc patients with oral-facial fibrosis using autologous AD-MSC lipotransfers. Significant improvements in mouth function, psychological status, and facial volume were observed after a median follow-up of 8 months.³⁰

Shoji *et al.* reported in 2019 on the long-term effects of BM-MSCs in 39 SSc patients with critical limb ischemia, showing significant pain reduction and a low amputation rate (12.8%) over 36.5 months.³¹

Del Papa *et al.* conducted a randomized controlled trial in 2019 with 25 SSc patients with ischemic digital ulcers. AD-MSC graft-

Table 2. Clinical characteristics of the study population distinguished by the immune-mediated inflammatory disease treated with mesenchymal stem cells.

	Psoriasis	Atopic dermatitis	Chronic spontaneous urticaria	Alopecia areata	Systemic sclerosis	Systemic lupus erythematosus
Total, n (%)	24 (100)	39 (100)	10 (100)	38 (100)	216 (100)	282 (100)
Sex, n (%)						
Female	10 (41.7)	11 (36.7)	7 (70)	18 (47.4)	158 (89.3)	92 (81.4)
Male	14 (58.3)	19 (63.3)	3 (30)	20 (52.6)	19 (10.7)	21 (18.6)
Age (years), mean (range)	59.9 (50-82)	28.1 (20-29)	39	31.4 (26-57)	48.2 (18-69)	35.2 (17-54)
Disease duration (years); range (min-max)	4; 32	≥0.5	8.2	0.8; 6	0.5; 15	1.3; 22
Disease type, n (%)						
Localized	0 (0)	0 (0)	0 (0)	34 (89.5)	74 (53.6)	4 (6.8)
Generalized	24 (100)	39 (100)	10 (100)	4 (10.5)	64 (46.4)	55 (93.2)
Previous immunosuppressants, n (%)						
Pts evaluable for immunosuppressants	17 (70.8)	0 (0)	10 (100)	18 (100)	0 (0)	249 (88.3)
no prior immunosuppressants	7 (41.2)	0 (0)	0 (0)	0 (0)	0 (0)	32 (12.8)
1 prior immunosuppressant	4 (23.5)	0 (0)	10 (100)	0 (0)	0 (0)	78 (31.3)
≥2 prior immunosuppressants	6 (35.3)	NA	NA	18 (100)	0 (0)	139 (55.8)
Response						
Pts evaluable for response, n (%)	24 (100)	36 (92.3)	10 (100)	38 (100)	177 (81.9)	263 (93.3)
Remission, n (%)	3 (12.5)	0 (0)	5 (50)	9 (23.7)	25 (14.1)	24 (9.1)
Time to remission (months); range (min-max)	1; 6		3; 3	1; 6	2; 2	1; 12
Duration of remission (months); range (min-max)	8; 18		NA	12; 12	3; 3	12; 12
Improvement, n (%)	10 (41.7)	18 (50)	3 (30)	29 (76.3)	152 (85.9)	239 (90.9)
Time to improvement (months); range (min-max)	1; 6	1; 3	6; 6	1; 16	1; 12	12; 12
Duration of Improvement (months); range (min-max)	6; 12	1; 22	NA	5; 12	3; 12	6; 12
AEs, n (%)						
Pts evaluable for AEs	24 (100)	38 (97.4)	10 (100)	38 (100)	134 (62.0)	187 (66.3)
Mild	22 (91.6)	15 (39.4)	0 (0)	22 (57.9)	40 (29.9)	41 (21.9)
General or local skin reaction	14 (63.6)	7 (46.6)	0 (0)	0 (0)	25 (62.5)	18 (43.9)
Skin infection	0 (0)	2 (13.3)	0 (0)	22 (100)	1 (2.5)	2 (4.9)
Gastrointestinal disorder	1 (4.5)	1 (6.7)	0 (0)	0 (0)	1 (2.5)	20 (48.8)
Respiratory infection	3 (13.6)	2 (13.3)	0 (0)	0 (0)	5 (12.5)	1 (2.4)
Other infections	0 (0)	2 (13.3)	0 (0)	0 (0)	0 (0)	0 (0)
Other or unspecified	4 (18.2)	5 (33.3)	0 (0)	0 (0)	8 (20.0)	0 (0)
Moderate-severe	1 (4.2)	0 (0)	0 (0)	0 (0)	1 (0.7)	5 (2.6)
Deaths	0 (0)	0 (0)	0 (0)	0 (0)	6 (4.5)	15 (8.0)

AE, adverse event; pts, patients; min, minimum; max, maximum; NA, not available.

ing reduced pain and increased nailfold capillary count after 4 and 8 weeks and healed all digital ulcers within 10 weeks.³²

In 2020, Park *et al.* treated 18 SSc patients with stromal vascular fraction (SVF) injections, resulting in improvements in microangiopathies, skin fibrosis, finger circumference, hand edema, quality of life, and digital ulcer healing, with a decrease in MRSS from 7.5 to 3 and no serious AEs.³³

In 2021, Wang *et al.* compared autologous fat grafting enriched with AD-MSCs or SVF to conventional fat grafting in 18 SSc patients, finding higher fat retention in the enriched groups at three and 6 months compared to the conventional group.³⁴

The results of these studies indicate that improvement or complete remission with MSCs is seen in up to 100% of SSc patients. Although deaths from all causes are reported in 6 patients, MSCs are generally well tolerated in these patients.

Systemic lupus erythematosus

Over the past 8 years, 6 clinical studies have explored the use of MSCs in treating SLE. In 2017, Wang *et al.* evaluated two IV infusions of UC-MSCs in 9 refractory SLE patients aged 20–46 years. Two patients achieved complete remission, 5 patients had partial responses, and 2 patients did not respond. No immediate AEs were noted, but long-term AEs included one death and 14 infections, attributed to disease activity and organ failure rather than MSC treatment. Blood analysis, organ functions, and tumorigenic marker levels remained unchanged.³⁵ Another 2017 study by Wang *et al.* involved 26 patients aged 16–54 years who underwent UC-MSC transplantation, with 17 showing clinical responses. Higher baseline IFN- γ and lower IL-6 levels predicted positive response to MSCs.³⁶

In 2018, Liang *et al.* reviewed 178 patients, with 32.5% achieving clinical remission and 27.5% partial remission after a single IV infusion of one million MSCs.²⁹ Hyperacute AEs, including palpitation and headache, occurred during the infusion. Death occurred in 14 patients due to underlying disease.

Barbado *et al.*, in an open-label study in 2018, reported on 3 severe SLE patients, finding two complete remissions and one partial response after allogeneic BM-MSC IV infusions.³⁷

Wen *et al.*'s 2019 study of 69 refractory patients showed 23% complete remission and 58% low disease activity after one or two UC/BM-MSC IV infusions.³⁸

In 2022, Kamen *et al.* observed clinical improvements up to 24 months in 4 out of 6 active SLE patients refractory to standard treatments after allogeneic UC-MSC IV infusions, with minimal AEs.³⁹

The main findings of these studies show that an improvement or a complete remission with MSCs is seen in up to 100% of SLE patients, with, in general, no serious AEs, except death from all causes in 15 patients.

by the maximum length of follow-up. The effect of MSC therapy was achievable after a single or a few administrations, with no serious AEs.

Most evidence on the use of MSCs for IMIDs still comes from clinical trials showing some promising results with no significant toxicity. Despite growing knowledge and experience with clinical application of MSCs, the cell dose and frequency of administration vary between trials, and the optimal dosing regimen remains undetermined. Preclinical studies are needed to further understand MSCs' systemic immune-modulating mechanisms and local immune microenvironment interactions to support their application across various inflammatory disorders.

Balancing the risks and benefits of therapy against the underlying disease is crucial. Indeed, cell therapy carries potential risks, high costs, regulatory requirements, and other complexities that must be justified by outcomes. Compared with HSCT, which has been reported to benefit severe IMIDs such as psoriasis, sometimes with apparent cure, MSCs have fewer complications and seem to be more tolerable for non-neoplastic disorders. Additionally, a single or a few MSC administrations may achieve a disease-modifying effect, unlike established targeted drugs requiring chronic treatment.

AEs with MSC therapy were common, occurring in up to 95.8% of patients with psoriasis. These events were predominantly mild, including skin reactions, gastrointestinal symptoms, and respiratory infections. Moderate and severe AEs were rare, occurring in 4.2% of psoriasis cases, 2.6% of patients with SLE, and 0.7% of patients with SSc, while deaths from all causes were reported in 6 out of 134 patients with SSc and 15 out of 187 patients with SLE with follow-up data.

In a few studies assessing MSCs for the treatment of SSc and SLE, other immunomodulators were concurrently used with MSC therapy.^{26,29–31,39} This could have significantly influenced the outcomes, as the use of immunomodulators may potentially affect both the efficacy and safety of MSC therapy.

Beyond the interest in advanced therapies, it should be noted that cell therapy is not the only option for the management of severe IMIDs. Among the various therapeutic strategies, including small molecules, biologics, and advanced cell therapy, only the latter offers a potential disease-modifying “curative” effect. Cell therapy, particularly in the form of MSCs, may offer a promising and tolerable option for IMIDs. MSC therapy may combine the benefits of current targeted therapeutics, which do not cause broad immunosuppression, and traditional immune modulators, which inhibit multiple inflammatory pathways and prevent the onset of paradoxical immune reactions seen with monoclonal antibodies. Finally, MSCs may meet the therapeutic needs of patients who are unresponsive to conventional immunomodulating agents and for whom effective alternatives are still lacking. In this context, there is a pressing need for controlled trials of MSCs in the management of refractory diseases, ideally coupled with mechanistic studies to define the mode of action.

We couldn't provide a clearer distinction between studies using allogeneic vs. autologous cells to enhance the analysis of MSC therapy due to the heterogeneity of the studies, the different outcomes, and dosages. Future studies are needed to define the optimal dosing and administration protocols for MSCs, as well as to standardize outcome measures and study designs. This will enable more robust comparisons across trials and foster a clearer understanding of their therapeutic potential. At the same time, other forms of cell therapy, such as regulatory T cells, fibroblasts, multilineage-differentiating stress-enduring cells, and induced pluripo-

Discussion and Conclusions

Published studies on patients affected by IMIDs who received treatment with MSCs show a clinical benefit, consisting of at least partial clinical improvement in most patients. Particularly, improvement or remission was seen in up to 100% of cases for AA, SSc, and SLE, and at least a clinical improvement was observed in most cases of IMIDs, also including psoriasis, AD, and CSU. The time to achieve this improvement or remission varied among disease groups and studies, reflecting different management strategies. Overall duration of improvement or remission was influenced

tent stem cells, should also be explored as alternative developmental approaches. Any decision to use cell therapy in the management of IMIDs should result from a multidisciplinary approach, involving transplant hematologists, experts in cell therapy, and clinicians with experience in the management of severe IMIDs. Future research should extend to other chronic inflammatory skin diseases, such as dermatomyositis, autoimmune bullous disorders (e.g., pemphigus), lichen planus, and cutaneous lupus erythematosus. Early evidence suggests that MSCs can modulate dysregulated immune responses, reduce inflammation, and support tissue repair in these conditions.¹⁷ However, beyond individual compassionate use of MSCs, future larger controlled trials are essential to further elucidate the role of MSCs in managing refractory inflammatory skin diseases.

References

- Dominici M, Le Blanc K, Mueller I, et al. Minimal criteria for defining multipotent mesenchymal stromal cells. The International Society for Cellular Therapy position statement. *Cytotherapy* 2006;8:315-7.
- Berebichez-Fridman R, Montero-Olvera PR. Sources and Clinical Applications of Mesenchymal Stem Cells: State-of-the-art review. *Sultan Qaboos Univ Med J* 2018;18:e264-77.
- Gao F, Chiu SM, Motan D, et al. Mesenchymal stem cells and immunomodulation: current status and future prospects. *Cell Death Dis* 2016;7:e2062.
- Wu Y, Chen L, Scott PG, Tredget EE. Mesenchymal stem cells enhance wound healing through differentiation and angiogenesis. *Stem Cells* 2007;25:2648-59.
- Falanga V, Iwamoto S, Chartier M, et al. Autologous bone marrow-derived cultured mesenchymal stem cells delivered in a fibrin spray accelerate healing in murine and human cutaneous wounds. *Tissue Eng* 2007;13:1299-312.
- Fu X, Liu G, Halim A, et al. Mesenchymal Stem Cell Migration and Tissue Repair. *Cells* 2019;8:784.
- Galipeau J, Sensébé L. Mesenchymal Stromal Cells: Clinical Challenges and Therapeutic Opportunities. *Cell Stem Cell* 2018;22:824-33.
- Squillaro T, Peluso G, Galderisi U. Clinical Trials With Mesenchymal Stem Cells: An Update. *Cell Transplant* 2016;25:829-48.
- Galleu A, Riffo-Vasquez Y, Trento C, et al. Apoptosis in mesenchymal stromal cells induces in vivo recipient-mediated immunomodulation. *Sci Transl Med* 2017;9:eaam7828.
- Lalu MM, McIntyre L, Pugliese C, et al. Safety of cell therapy with mesenchymal stromal cells (SafeCell): a systematic review and meta-analysis of clinical trials. *PLoS One* 2012;7:e47559.
- Wuchter P, Bieback K, Schrezenmeier H, et al. Standardization of Good Manufacturing Practice-compliant production of bone marrow-derived human mesenchymal stromal cells for immunotherapeutic applications. *Cytotherapy* 2015;17:128-39.
- Gnecchi M, He H, Noiseux N, et al. Evidence supporting paracrine hypothesis for Akt-modified mesenchymal stem cell-mediated cardiac protection and functional improvement. *FASEB J* 2006;20:661-9.
- Badillo AT, Beggs KJ, Javazon EH, et al. Murine bone marrow stromal progenitor cells elicit an in vivo cellular and humoral alloimmune response. *Biol Blood Marrow Transplant* 2007;13:412-22.
- Ghannam S, Pène J, Moquet-Torcy G, et al. Mesenchymal stem cells inhibit human Th17 cell differentiation and function and induce a T regulatory cell phenotype. *J Immunol* 2010;185:302-12.
- Griffin MD, Ritter T, Mahon BP. Immunological aspects of allogeneic mesenchymal stem cell therapies. *Hum Gene Ther* 2010;21:1641-55.
- Gu LH, Zhang TT, Li Y, et al. Immunogenicity of allogeneic mesenchymal stem cells transplanted via different routes in diabetic rats. *Cell Mol Immunol* 2015;12:444-55.
- Kim KH, Blasco-Morente G, Cuende N, Arias-Santiago S. Mesenchymal stromal cells: properties and role in management of cutaneous diseases. *J Eur Acad Dermatol Venerol* 2017;31:414-23.
- Yao D, Ye S, He Z, et al. Adipose-derived mesenchymal stem cells (AD-MSCs) in the treatment for psoriasis: results of a single-arm pilot trial. *Ann Transl Med* 2021;9:1653.
- Cheng L, Wang S, Peng C, et al. Human umbilical cord mesenchymal stem cells for psoriasis: a phase 1/2a, single-arm study. *Signal Transduct Target Ther* 2022;7:263.
- Kim HS, Lee JH, Roh KH, et al. Clinical Trial of Human Umbilical Cord Blood-Derived Stem Cells for the Treatment of Moderate-to-Severe Atopic Dermatitis: Phase I/IIa Studies. *Stem Cells* 2017;35:248-55.
- Shin HT, Lee SH, Yoon HS, et al. Long-term efficacy and safety of intravenous injection of clonal mesenchymal stem cells derived from bone marrow in five adults with moderate to severe atopic dermatitis. *J Dermatol* 2021;48:1236-42.
- Özgül Özdemir RB, Özdemir AT, Kırmaz C, et al. Mesenchymal Stem Cells: a Potential Treatment Approach for Refractory Chronic Spontaneous Urticaria. *Stem Cell Rev Rep* 2021;17:911-22.
- Elmaadawi IH, Mohamed BM, Ibrahim ZAS, et al. Stem cell therapy as a novel therapeutic intervention for resistant cases of alopecia areata and androgenetic alopecia. *J Dermatolog Treat* 2018;29:431-40.
- Czarnecka A, Odziomek A, Murzyn M, et al. Wharton's jelly-derived mesenchymal stem cells in the treatment of four patients with alopecia areata. *Adv Clin Exp Med* 2021;30:211-8.
- Lee SB, Shin HT, Byun JW, et al. Clinical efficacy of adipocyte-derived stem cells conditioned media combined with micro-injury in refractory patch of alopecia areata. *Arch Dermatol Res* 2022;314:527-32.
- Zhang H, Liang J, Tang X, et al. Sustained benefit from combined plasmapheresis and allogeneic mesenchymal stem cells transplantation therapy in systemic sclerosis. *Arthritis Res Ther* 2017;19:165.
- Blezien O, D'Andrea F, Nicoletti GF, Ferraro GA. Effects of Fat Grafting Containing Stem Cells in Microstomia and Microcheilia Derived from Systemic Sclerosis. *Aesthetic Plast Surg* 2017;41:839-44.
- Virzi F, Bianca P, Giammona A, et al. Combined platelet-rich plasma and lipofilling treatment provides great improvement in facial skin-induced lesion regeneration for scleroderma patients. *Stem Cell Res Ther* 2017;8:236.
- Liang J, Zhang H, Kong W, et al. Safety analysis in patients with autoimmune disease receiving allogeneic mesenchymal stem cells infusion: a long-term retrospective study. *Stem Cell Res Ther* 2018;9:312.
- Almadori A, Griffin M, Ryan CM, et al. Stem cell enriched

- lipotransfer reverses the effects of fibrosis in systemic sclerosis. *PLoS One* 2019;14:e0218068.
31. Shoji K, Yanishi K, Yoshimi R, et al. Impact of Therapeutic Angiogenesis Using Autologous Bone Marrow-Derived Mononuclear Cells Implantation in Critical Limb Ischemia With Scleroderma - Subanalysis of the Long-Term Clinical Outcomes Survey. *Circ J* 2019;83:662-71.
 32. Del Papa N, Di Luca G, Andracco R, et al. Regional grafting of autologous adipose tissue is effective in inducing prompt healing of indolent digital ulcers in patients with systemic sclerosis: results of a monocentric randomized controlled study. *Arthritis Res Ther* 2019;21:7.
 33. Park Y, Lee YJ, Koh JH, et al. Clinical Efficacy and Safety of Injection of Stromal Vascular Fraction Derived from Autologous Adipose Tissues in Systemic Sclerosis Patients with Hand Disability: A Proof-Of-Concept Trial. *J Clin Med* 2020;9:3023.
 34. Wang C, Long X, Si L, et al. A pilot study on ex vivo expanded autologous adipose-derived stem cells of improving fat retention in localized scleroderma patients. *Stem Cells Transl Med* 2021;10:1148-56.
 35. Wang D, Niu L, Feng X, et al. Long-term safety of umbilical cord mesenchymal stem cells transplantation for systemic lupus erythematosus: a 6-year follow-up study. *Clin Exp Med* 2017;17:333-40.
 36. Wang D, Wang S, Huang S, et al. Serum IFN- γ Predicts the Therapeutic Effect of Mesenchymal Stem Cells Transplantation in Systemic Lupus Erythematosus Patients. *Stem Cells Transl Med* 2017;6:1777-85.
 37. Barbado J, Tabera S, Sánchez A, García-Sancho J. Therapeutic potential of allogeneic mesenchymal stromal cells transplantation for lupus nephritis. *Lupus* 2018;27:2161-5.
 38. Wen L, Labopin M, Badoglio M, et al. Prognostic Factors for Clinical Response in Systemic Lupus Erythematosus Patients Treated by Allogeneic Mesenchymal Stem Cells. *Stem Cells Int* 2019;2019:7061408.
 39. Kamen DL, Wallace C, Li Z, et al. Safety, immunological effects and clinical response in a phase I trial of umbilical cord mesenchymal stromal cells in patients with treatment refractory SLE. *Lupus Sci Med* 2022;9:e000704.

Received: 8 August 2025; Accepted: 8 June 2025.

Conflict of interest: the authors declare no potential conflict of interest.

Ethics approval and consent to participate: not applicable.

Availability of data and materials: all data generated or analyzed during this study are included in this published article.

Publisher's note: all claims expressed in this article are solely those of the authors and do not necessarily represent those of their affiliated organizations, or those of the publisher, the editors and the reviewers. Any product that may be evaluated in this article or claim that may be made by its manufacturer is not guaranteed or endorsed by the publisher.

This work is licensed under a Creative Commons Attribution-NonCommercial 4.0 International License (CC BY-NC 4.0).