

Ultrasound monitoring of hidradenitis suppurativa fistulas in treatment with adalimumab

Raffaele Dante Caposiena Caro,¹ Giulia Bazzacco,² Enrico Zelin,² Vanessa Mazzoletti,² Nicola Di Meo,¹ Iris Zalaudek¹

¹Dermatology Clinic, Hospital Maggiore of Trieste, University of Trieste; ²Institute of Dermatology, Santa Maria della Misericordia University Hospital, Udine, Italy

Correspondence: Raffaele Dante Caposiena Caro, MD, PhD, Department of Dermatology Trieste and Gorizia, Hospital Maggiore, University of Trieste, Piazza dell'Ospitale, 1, 34125 Trieste, Italy. Tel.: +39.0403992056
E-mail: dcaposiena@hotmail.com

Key words: hidradenitis suppurativa; ultrasound; adalimumab.

Contributions: RDCC, data curation and analysis, writing – original draft preparation, conceptualization, and methodology; GB, VM, EZ, writing – original draft preparation; NDM, IZ, supervision. All authors have read and approved the final version of the manuscript and agreed to be accountable for all aspects of the work.

Conflicts of interest: RDCC, payment or honoraria for lectures, presentations, speakers bureaus, manuscript writing or educational events, from Novartis, Eli Lilly, Sanofi and Pfizer; NDM, payment or honoraria for lectures, presentations, speakers bureaus, manuscript writing or educational events from Almirall, Sunpharma, MSD, Sanofi and Pfizer; IZ, payment or honoraria for lectures, presentations, speakers bureaus, manuscript writing or educational events from Sanofi Genzyme, Sunpharma, Novartis, MSD, BMS, Philogen, Biogena, La Roche Posay, Kyowara Kirin, Fotofinder, Mall.inckrodt, Cieffe Derma, Pierre Fabre, Regeneron, Canova, Almirall, Beiersdorf, support for attending meetings and/or travel from Difa Cooper, and participation on a Data Safety Monitoring Board or Advisory Board for Philogen. None of the contributing authors have any conflict of interest, including specific financial interests or relationships and affiliations relevant to the subject matter or discussed materials in the manuscript.

Ethics approval and consent to participate: in accordance with the Italian research regulations (D.Lgs. 101/2018), ethical board approval is waived for retrospective studies, as patients provide consent for the use of clinical data for research purposes at hospitalization. All examinations adhered to the Helsinki principles of medical ethics.

Consent for publication: the patients in this manuscript have given written informed consent to the publication of their case details and any accompanying images.

Availability of data and materials: the data that support the findings of this study are available from the corresponding author upon reasonable request.

Received: 20 August 2024.

Accepted: 27 March 2025.

This work is licensed under a Creative Commons Attribution-NonCommercial 4.0 International License (CC BY-NC 4.0).

©Copyright: the Author(s), 2025

Licensee PAGEPress, Italy

Dermatology Reports 2025; 17:10124

doi:10.4081/dr.2025.10124

Publisher's note: all claims expressed in this article are solely those of the authors and do not necessarily represent those of their affiliated organizations, or those of the publisher, the editors and the reviewers. Any product that may be evaluated in this article or claim that may be made by its manufacturer is not guaranteed or endorsed by the publisher.

Abstract

Recently, ultrasound has emerged as an important tool for studying hidradenitis suppurativa (HS), enabling differentiation between abscesses and fistulas and the assessment of various disease features. However, data on the use of ultrasound to evaluate treatment response to medical therapy remain limited. This study aims to evaluate the clinical utility of ultrasound in monitoring disease activity in HS patients treated with adalimumab over a 52-week period. This research employs a retrospective approach to analyze ultrasound scores related to fibrosis, edema, power-Doppler (PD) signal, and resistive index (RI) at baseline and after 52 weeks of adalimumab treatment. In total, 311 fistulas from 69 patients were included. Multivariate regression analysis revealed that PD score and edema were associated with the International Hidradenitis Suppurativa Severity Score System (IHS4)-55, as well as with changes in the Dermatology Life Quality Index (DLQI) and pain Visual Analogue Scale (VAS) scores. Moreover, at baseline, healed and non-healed fistulas showed significant differences in PD signal, fibrosis, edema, and RI. Limitations include the retrospective design of the study, a limited population size, and the absence of a control group. However, our data provide evidence that ultrasound can be a reliable tool for assessing patients' responses to medical therapies.

Introduction

Hidradenitis suppurativa (HS) is a chronic, inflammatory, and recurrent follicular skin disease that causes painful, deep-seated, and inflamed lesions in apocrine gland-bearing areas.^{1,2} Commonly localized in the axillae, inguinal, and anogenital regions, HS significantly impacts the patient's quality of life. The primary goal of HS treatment is to reduce inflammatory lesion and fistula counts, alleviate pain scores, and prevent scar development from baseline.^{1,2} Clinical measures such as the International Hidradenitis Suppurativa Severity Score System (IHS4) and its novel dichotomous version IHS4-55, based on a 55% reduction in the total score, have been developed for assessing HS in trials and daily practice.³

Adalimumab, a fully human IgG1 monoclonal antibody specific for tumor necrosis factor (TNF)- α , is currently approved for the treatment of a wide range of inflammatory diseases, including moderate-to-severe plaque psoriasis and moderate-to-severe HS.^{2,3} In recent years, HS has been extensively studied and standardized through ultrasound, enabling differentiation between a draining abscess and a draining fistula.⁴ Ultrasound also allows the evaluation of the edema extension, the grade of fibrosis, and vascularization levels, features that cannot be clinically examined.⁴ However, there are still limited data on the use of ultrasound to assess treatment response to adalimumab.^{4,11}

The aim of this study is to evaluate the clinical usefulness of

ultrasound in monitoring disease activity in patients with HS treated with adalimumab for 52 weeks.

Materials and Methods

This retrospective study included 69 patients diagnosed with HS, enrolled from December 2019 to December 2023. Subjects who participated in the study were patients initiating adalimumab treatment due to an insufficient response to conventional therapies (antibiotics and/or retinoids). All patients included in the study received adalimumab 40 mg for 52 weeks and underwent ultrasound examinations at baseline and at 52 weeks. In accordance with the Italian research regulations (D.Lgs. 101/2018), ethical approval is waived for retrospective studies, as patients provide consent for the use of clinical data for research purposes at hospitalization. All examinations adhered to the principles of medical ethics outlined in the Declaration of Helsinki.

Baseline clinical data included age, gender, body mass index (BMI), smoking habit, disease duration/onset, and comorbidities. Disease activity was assessed both at baseline and at 52 weeks, using the following scores: Hurley stage, IHS4, IHS4-55, Dermatology Life Quality Index (DLQI), and the pain Visual Analogue Scale (VAS). The IHS4 was calculated using the follow-

ing formula: (nodules number \times 1) + (abscesses number \times 2) + (fistula number \times 4).³

The ultrasound assessment was conducted by evaluating the grade of edema, fibrosis, and vascularization using a MyLabOne ultrasound machine (Esaote, Genoa, Italy) with a 10-18 MHz linear transducer. All assessments were performed by the same investigator, who completed a training program. Only fistulas were included in this study due to their prolonged presence, enabling long-term follow-up. Clinical images of lesions were used to identify fistulas during follow-up. Fistulas that were surgically treated either previously or during the study were excluded to minimize potential bias related to fibrotic tissue. Ultrasound scoring of fibrosis, edema, power-Doppler (PD) signal, and resistive index (RI) were performed as follows in accordance with the definition reported in the literature:^{6,12-14} i) fibrosis: absent (0), at the periphery of the fistulous tracts (1), invading part of the fistulous tract, generating a halo in the periphery (2); ii) edema: absent (0), hypodermal hyperechogenicity (1), anechoic fluid between the fatty lobules of the hypodermis (2); iii) PD: absent (0), few color spots are detectable (1), some flow signals are visible (2), multiple flow signals are visible in the lesion (3); and iv) RI: high resistance if the RI was >0.7 or low resistance if it was <0.7 , it was measured on perilesional or intralesional flows, respectively, in the case of peripheral or mixed Doppler signal.

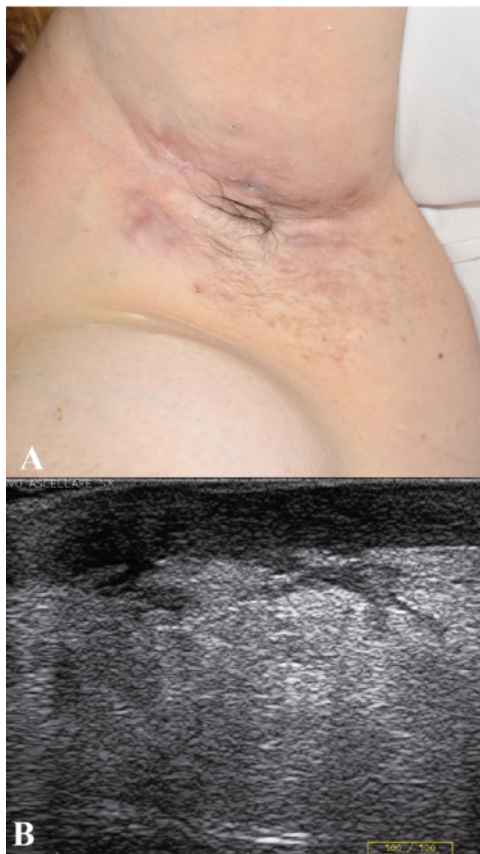


Figure 1. A) Clinical picture of the right armpit at baseline; B) ultrasound picture of the draining tunnel in the right armpit at baseline (fibrosis score 1, edema score 2).

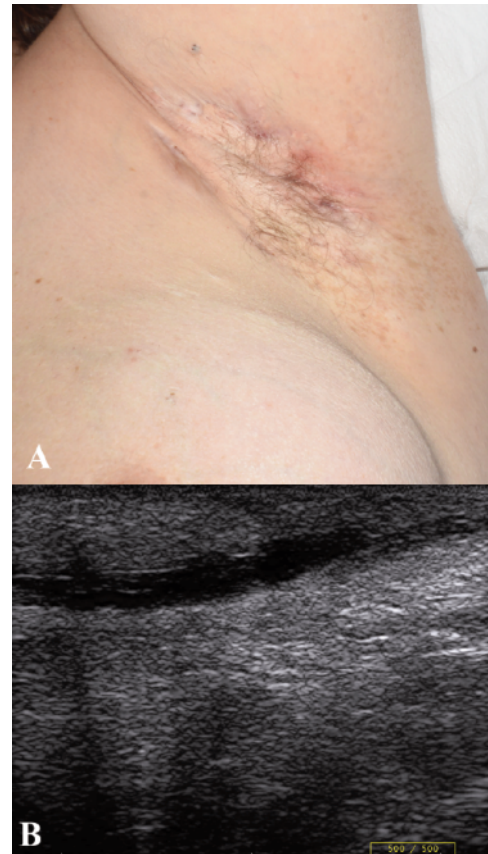


Figure 2. A) Clinical picture of the right armpit after 52 weeks of treatment; B) ultrasound picture of the draining tunnel in the right armpit after 52 weeks of treatment (fibrosis score 1, edema score 0).

Data were described as numbers with percentages (%) for nominal variables and as mean with standard deviation (SD) for continuous variables. Changes in ultrasound findings such as edema, fibrosis, PD signal, and RI between baseline and week 52 were assessed using the Wilcoxon signed-rank test. The variations in ultrasound findings between responder and non-responder groups (based on IHS4-55) and between healed and non-healed fistulas at baseline were evaluated using the Mann-Whitney test. Δ PD, Δ DLQI, Δ pain-VAS, and Δ RI were defined as the differences between values at baseline and week 52. The correlation between clinical response and ultrasound findings at week 52 was calculated using multivariate regression analysis of non-healed fistulas. Statistical significance was considered at $p < 0.05$. All statistical analyses were performed using IBM SPSS Statistics 27.0 (IBM Corp., Armonk, NY, USA).

Results

In total, 311 fistulas from 69 patients (34 females and 35 males) who received adalimumab for 52 weeks were assessed in this study (Figures 1 and 2). The average age of the patients was 36.6 years. Baseline characteristics, including age of onset, BMI, and comorbidities are illustrated in Table 1. The localization of fistulas at baseline and week 52 is presented in Table 2. The average length, thickness, and RI of the 311 fistulas at baseline were 34.61 ± 20.76 mm, 4.30 ± 2.36 mm, and 0.362 ± 0.127 , respectively.

After 52 weeks of treatment with adalimumab, significant

improvements were observed in IHS4 (baseline: 25.3 ± 15.4 , week 52: 16.9 ± 16.5 , $Z = -6.920$), DLQI (baseline: 16.2 ± 8.3 , week 52: 8.8 ± 7.8 , $Z = -7.126$), and pain-VAS (baseline: 6.5 ± 2.6 , week 52: 3.6 ± 2.6 , $Z = -7.055$), compared to baseline ($p < 0.001$ for all). Treatment response, based on IHS4-55, was achieved by 29/69 patients (42.0%). In these patients, 68 fistulas were observed at baseline and 16 at week 52.

Table 1. Patients' baseline characteristics.

Variables	Results
Number of patients	69
Gender	
Female, n (%)	34 (49.3)
Male, n (%)	35 (50.7)
Age 36.6 ± 13.0	
Age of onset	20.5 ± 9.5
BMI	28.1 ± 5.2
Smokers	55 (79.7)
Comorbidities, n (%)	30 (43.4)
Polycystic ovary syndrome	10 (14.5)
Hypertension	7 (10.1)
Psoriasis	7 (10.1)
Hashimoto thyroiditis	6 (8.7)
Nodules abscesses, n	316
Fistulas, n	311

BMI, body mass index.

Table 2. Fistula localization at baseline and at week 52.

Characteristics	Baseline, n (%)	Week 52, n (%)	Week 52 (healed), n (%)
Axillary			
Left	63 (20.3)	48 (15.4)	15 (4.8)
Right	59 (19.0)	42 (13.5)	17 (5.5)
Groin			
Left	47 (15.1)	43 (13.8)	4 (1.3)
Right	59 (19.0)	59 (19.0)	0 (0.0)
Gluteal			
Left	20 (6.4)	6 (1.9)	14 (4.5)
Right	23 (7.4)	3 (1.0)	20 (6.4)
Trunk	38 (12.2)	24 (7.7)	14 (4.5)
Neck	2 (0.6)	2 (0.6)	0 (0.0)
Dermal	58 (18.6)	22 (7.1)	36 (11.6)
Dermal-hypodermal	148 (47.6)	100 (32.2)	48 (15.4)
Complex	66 (21.2)	66 (21.2)	0 (0.0)
Subcutaneous	39 (12.5)	39 (12.5)	0 (0.0)
Power-Doppler			
Peripheral	148 (47.6)	95 (30.5)	53 (17.0)
Mixed	163 (52.4)	155 (49.8)	8 (2.6)

Table 3. Comparison of ultrasound unhealed fistulas' characteristics at baseline and at week 52.

	Baseline	Week 52	Z	p
Power Doppler	2.17 ± 0.55	1.93 ± 0.71	-6.337	<0.001
Fibrosis	1.62 ± 0.66	1.67 ± 0.60	-2.972	0.003
Edema	1.25 ± 0.47	1.17 ± 0.44	-4.243	<0.001
Resistive index	0.335 ± 0.127	0.3632 ± 0.151	-5.056	<0.001
Length (mm)	37.18 ± 21.96	36.71 ± 21.83	-3.396	<0.001
Thickness (mm)	4.62 ± 2.32	4.26 ± 2.31	-4.801	<0.001

After 52 weeks of therapy, 84 out of 311 fistulas (27%) were healed. Adalimumab for 52 weeks induced significant improvement in PD signal, fibrosis, edema, and RI compared to baseline (Tables 2 and 3). Multivariate regression analysis between disease activity composites and ultrasound findings showed that PD score was related to IHS4-55, Δ DLQI, and Δ pain-VAS (Table 3). Additionally, relationships between edema and both IHS4-55 and Δ pain-VAS were found. However, no correlations between disease activity composites and fibrosis were observed. Changes in ultrasound findings were compared based on IHS4-55 improvement. There were significant changes in PD signal and edema, but no significant changes in fibrosis and RI were found (Tables 4 and 5). Baseline differences between healed and non-healed fistulas were also analyzed. Significant differences at baseline were observed for PD signal, fibrosis, edema, and RI when comparing healed-*vs.* non-healed fistulas (Table 6).

Discussion

The etiology of HS is incompletely understood, but current assumptions suggest that follicular hyperkeratinization leads to occlusion, rupture, and inflammation. TNF- α is believed to be a primary driver of this inflammatory process, and, indeed, TNF- α concentration is significantly higher in the serum and skin of HS patients compared to healthy individuals.^{1,2} Similarly, HS lesional skin shows increased levels of interleukin (IL)-1 β , IL-10, and IL-17 compared to healthy skin and psoriatic plaques. Despite the wide array of inflammatory cytokines involved in the pathogenesis of HS, anti-TNF- α therapy appears to reduce the majority of these proinflammatory cytokines.^{1,2}

Tight regulation of the TNF- α signaling pathway has emerged as a crucial therapeutic strategy in HS, as reported by several studies wherein adalimumab markedly improved clinical symptoms

Table 4. Correlation between changes of IHS4-55 and ultrasound scores of survived fistulas.

Survived fistulas Characteristic	B	CI	p
IHS4-55			
Δ Power Doppler	0.137	0.074-0.201	<0.001
Δ fibrosis	0.086	-0.035-0.207	0.164
Δ edema	0.249	0.133-0.365	<0.001
Δ DLQI			
Δ Power Doppler	1.238	0.344-2.133	0.007
Δ fibrosis	1.432	-0.275-3.139	0.100
Δ edema	0.699	-0.931-2.330	0.399
Δ pain-VAS			
Δ Power Doppler	0.768	0.432-1.104	<0.001
Δ fibrosis	0.868	0.227-1.509	0.008
Δ edema	1.347	0.735-1.959	<0.001

CI, confidence interval; IHS4, International Hidradenitis Suppurativa Severity Score System; Δ , changes between baseline and week 52; DLQI, Dermatology Life Quality Index; VAS, Visual Analogue.

Table 5. Comparison of changes in ultrasound scores from baseline to week 52 between responder and non-responder patients.

Characteristic	Group	Baseline	Week 52	Δ	Z	p
Power Doppler	Responder	2.25 \pm 0.45	1.50 \pm 0.89	0.23 \pm 0.50	-4.177	<0.001
	Non-responder	2.16 \pm 0.55	1.97 \pm 0.69			
Fibrosis	Responder	1.13 \pm 0.81	1.13 \pm 0.81	-0.05 \pm 0.26	-0.889	0.374
	Non-responder	1.66 \pm 0.63	1.72 \pm 0.57			
Edema	Responder	1.38 \pm 0.50	1.00 \pm 0.52	0.08 \pm 0.27	-4.531	<0.001
	Non-responder	1.24 \pm 0.47	1.18 \pm 0.43			
Resistive index	Responder	0.425 \pm 0.169	0.463 \pm 0.213	-0.278 \pm 0.791	-0.917	0.359
	Non-responder	0.328 \pm 0.121	0.355 \pm 0.143			

Δ , changes between baseline and week 52.

Table 6. Mann-Whitney test of baseline ultrasound findings based on healed *vs.* non-healed fistulas.

Characteristic	Group	Baseline	Z	p
Power Doppler	Responder	1.33 \pm 0.47	-10.243	<0.001
	Non-responder	2.17 \pm 0.55		
Fibrosis	Responder	0.31 \pm 0.46	-12.136	<0.001
	Non-responder	1.62 \pm 0.66		
Edema	Responder	0.67 \pm 0.47	-8.310	<0.001
	Non-responder	1.24 \pm 0.47		
Resistive index	Responder	0.436 \pm 0.094	-6.624	<0.001
	Non-responder	0.335 \pm 0.127		

and signs of HS.^{2,3} However, there are scant data for ultrasound-based skin inflammation and damage monitoring using both grayscale and PD signal after treatment with adalimumab.⁵⁻¹¹ This study showed that adalimumab treatment for 52 weeks may reduce the progression of fibrosis in HS patients and significantly improve ultrasound-detected edema and PD signal.

Connective tissue and fibroblasts play an essential role in HS-related inflammation and contribute to skin damage. Therefore, skin connective tissue and fibroblasts are potential therapeutic targets in HS. Experimental evidence indicates that TNF- α can act directly on structural cells (fibroblasts) and immune cells (macrophages, T cells) to drive pro-fibrotic and anti-fibrotic effects.¹⁵ Indeed, Izaldi *et al.* showed that TNF can convert human dermal fibroblasts into myofibroblasts *via* activation of Wnt signaling, while TNF inhibition through neutralizing antibodies reverses the myofibroblast phenotype, suggesting TNF as a potential therapeutic target.¹⁶

Studies also support the immunologic effect of adalimumab on HS lesional skin inflammation, wherein interferon-gamma (IFN γ), IL-2, IL-22, frequency of Th17 cells, and T-reg cell ratio exhibited a significant reduction after adalimumab therapy.¹⁷ Moreover, some evidence suggests that PD signaling is a valid imaging-based biomarker in HS that correlates with patient pain score and severity assessment.^{4,6,15-18}

Our study confirmed that adalimumab is an effective therapeutic strategy to reduce skin inflammation in HS patients. Clinically, this was supported by the number of patients who achieved IHS4-55 and the improvement of clinical scores at week 52 compared to baseline. Sonographically, this was evidenced by the marked decrease in edema and PD scores. Interestingly, we found an increase in RI after treatment with adalimumab, suggesting reduced inflammation and consequent vasodilation in HS lesional skin.

PD ultrasound is increasingly used to assess active inflammation in HS by detecting increased microvascular blood flow in affected tissues.^{4,11-12,18} However, there is still limited evidence linking ultrasound grayscale and PD intensity scores to clinical disease activity. In this study, variations in PD signal from baseline to week 52 correlated with changes in all clinical scores, suggesting that PD signal could serve as a reliable marker of disease activity in HS. Changes in edema were associated with IHS4-55 and pain-VAS variations, whereas fibrosis was linked to pain-VAS changes, indicating that ultrasound grayscale may effectively reflect disease activity in HS. Additionally, the variations of PD and edema scores were higher in responder than non-responder patients, suggesting a good correlation between these two ultrasound scores and response to medical treatment. Furthermore, PD and edema score variations were more pronounced in responder patients, underscoring their correlation with treatment response.

Previous studies have shown that fibrotic scarring – evidenced by hyperechoic or hypoechoic tissue with a laminar or bandlike disposition – is associated with a poor response to treatment.^{6,12} Our study corroborated this observation, as unhealed fistulas exhibited higher fibrosis levels than healed ones. Despite treatment, fibrosis tended to increase progressively in unhealed fistulas, as reported in the literature.⁷ Additionally, fibrosis did not correlate with IHS4-55, whereas both edema and PD signal showed a consistent decrease from baseline to week 52, with greater decreases in responders than non-responders, and correlated with IHS4-55, pain-VAS, and DLQI. Furthermore, edema and PD signals appear to be more reliable markers of treatment response, both for individual lesions and overall, compared to fibrosis, which may better serve as a baseline predictor of poor response in individual fistulas. We hypothesize that this could be related to the

nature of edema and vascularization, which are more closely associated with inflammation and its fluctuations, unlike fibrosis, which is a slow and progressive process and less sensitive to changes in inflammation. Overall, ultrasound may help identify fistulas with a higher likelihood of healing under medical treatment and those that might benefit from alternative approaches.

This study has some limitations, including its retrospective design, small sample size, and lack of a control group. Additionally, due to the study's focus on fistulas, ultrasound assessment might not have fully captured the patients' overall inflammatory changes.

Conclusions

Our data indicate that 52 weeks of adalimumab treatment has a beneficial effect on skin inflammation in patients with moderate-to-severe HS and that ultrasound can reliably assess response to therapy. Long-term follow-up studies are warranted to confirm these findings.

References

1. Vossen ARJV, van der Zee HH, Prens EP. Hidradenitis Suppurativa: A Systematic Review Integrating Inflammatory Pathways Into a Cohesive Pathogenic Model. *Front Immunol* 2018;9:2965.
2. Seyed Jafari SM, Hunger RE, Schlapbach C. Hidradenitis Suppurativa: Current Understanding of Pathogenic Mechanisms and Suggestion for Treatment Algorithm. *Front Med (Lausanne)* 2020;7:68.
3. Daoud M, Suppa M, Benhadou F, et al. Overview and comparison of the clinical scores in hidradenitis suppurativa: A real-life clinical data. *Front Med (Lausanne)* 2023;10:1145152.
4. Wortsman X. Update on Ultrasound Diagnostic Criteria and New Ultrasound Severity and Activity Scorings of Hidradenitis Suppurativa: Modified SOS-HS and US-HSA. *J Ultrasound Med* 2024;43:207-13.
5. Krajewski PK, Jfri A, Ochando-Ibernón G, Martorell A. Ultrasonographic railway sign in tunnels as a new independent risk factor of adalimumab failure in hidradenitis suppurativa. *J Am Acad Dermatol* 2023;88:732-4.
6. Caposiena Caro RD, Solivetti FM, Candi E, Bianchi L. Clinical and Power-Doppler ultrasound features related with persistence of fistulous tracts under treatment with adalimumab in hidradenitis suppurativa: 4 years of follow-up. *Dermatol Ther* 2021;34:e14804.
7. Nazzaro G, Calzari P, Passoni E, et al. Vascularization and fibrosis are important ultrasonographic tools for assessing response to adalimumab in hidradenitis suppurativa: Prospective study of 32 patients. *Dermatol Ther* 2021;34:e14706.
8. Chiricozzi A, Giovanardi G, Garcovich S, et al. Clinical and Ultrasonographic Profile of Adalimumab-treated Hidradenitis Suppurativa Patients: A Real-life Monocentric Experience. *Acta Derm Venereol* 2020;100:adv00172.
9. Caposiena Caro RD, Cannizzaro MV, Tartaglia C, Bianchi L. Clinical response rate and flares of hidradenitis suppurativa in the treatment with adalimumab. *Clin Exp Dermatol* 2020;45:438-44.
10. Caposiena Caro RD, Cannizzaro MV, DI Raimondo C, et al. Long-term efficacy and safety of adalimumab on a severe case of hidradenitis suppurativa. *Ital J Dermatol Venerol*

- 2021;156:101-2.
11. Lacarrubba F, Dini V, Napolitano M, et al.; Italian Ultrasound Working Group. Ultrasonography in the pathway to an optimal standard of care of hidradenitis suppurativa: the Italian Ultrasound Working Group experience. *J Eur Acad Dermatol Venereol* 2019;33:10-4.
 12. Caposiena Caro RD, Solivetti FM, Bianchi L. Power Doppler ultrasound assessment of vascularization in hidradenitis suppurativa lesions. *J Eur Acad Dermatol Venereol* 2018;32:1360-7.
 13. Wortsman X, Castro A, Figueroa A. Color Doppler ultrasound assessment of morphology and types of fistulous tracts in hidradenitis suppurativa (HS). *J Am Acad Dermatol* 2016;75:760-7.
 14. Wortsman X, Reyes-Baraona F, Ramirez-Cornejo C, et al. Can Ultrasound Examinations Generate Pain in Hidradenitis Suppurativa Patients? Results from a Multicentric Cross-Sectional Study. *Dermatology* 2023;239:277-82.
 15. Steele H, Cheng J, Willicut A, et al. TNF superfamily control of tissue remodeling and fibrosis. *Front Immunol.* 2023;14:1219907.
 16. Izadi D, Layton TB, Williams L, et al. Identification of TNFR2 and IL-33 as therapeutic targets in localized fibrosis. *Sci Adv* 2019;5:eaay0370.
 17. Moran B, Sweeney CM, Hughes R, et al. Hidradenitis Suppurativa Is Characterized by Dysregulation of the Th17:Treg Cell Axis, Which Is Corrected by Anti-TNF Therapy. *J Invest Dermatol* 2017;137:2389-95.
 18. Grand D, Frew JW, Navrazhina K, Krueger JG. Doppler ultrasound-based noninvasive biomarkers in hidradenitis suppurativa: evaluation of analytical and clinical validity. *Br J Dermatol* 2021;184:688-96.