

Acral lentiginous melanoma with subsequent spontaneous vitiligo vulgaris: a case report and literature review

Ronak S. Ahmed,^{1,2} Rozhgar R. Ali,³ Dilan S. Hiwa,¹ Abdullah K. Ghafour,¹ Shvan O. Siddiq,^{2,4} Saywan K. Asaad,^{1,3} Ari M. Abdullah,^{1,5} Rawa M. Ali,^{1,6} Zuhair D. Hammood,^{1,7,8} Rebaz M. Ali,^{1,9} Fahmi H. Kakamad^{1,3,7}

¹Scientific Affairs Department, Smart Health Tower, Sulaymaniyah; ²Dermatology Teaching Center for Treating Skin Diseases, Sulaimani Directorate of Health, Sulaymaniyah; ³College of Medicine, University of Sulaimani, Sulaymaniyah; ⁴Kurdistan Board of Medical Specialties, Erbil; ⁵Department of Pathology, Sulaymaniyah Teaching Hospital; ⁶Department of Histopathology, Hospital for Treatment of Victims of Chemical Weapons, Halabja; ⁷Kscien Organization, Sulaymaniyah; ⁸Department of Surgery, Tikrit Teaching Hospital, Saladin; ⁹Hiwa Hospital, Ministry of Health, Sulaymaniyah, Iraq

Correspondence: Dr. Fahmi H. Kakamad, College of Medicine, University of Sulaimani, Madam Mitterrand Street, 46001 Sulaymaniyah, Kurdistan, Iraq.
E-mail: fahmi.hussein@univsul.edu.iq

Key words: malignant melanoma; acral lentiginous melanoma; vitiligo vulgaris; generalized vitiligo; leukoderma; depigmentation.

Contributions: RSA was responsible for the conception of the study and conducting a literature search; DSH, AKG, and FHK conducted the literature review, study design, and manuscript writing; RRA, SOS, SKA, ReMA, and ZDH participated in the literature review, study design, critical revision of the manuscript, and processing of the figures; FHK and SOS confirmed the authenticity of all raw data; AMA and RaMA are the pathologists who performed the histopathological diagnosis. All authors have read and approved the final manuscript.

Conflict of interest: the authors declare that they have no competing interests.

Ethics approval and consent to participate: no ethical committee approval was required for this case report, because this article does not contain any prospective interventions in human participants or animals. Informed consent was obtained from the patient included in this study.

Consent for publication: written informed consent was obtained from the patient for the publication of the present case report and any accompanying images.

Availability of data and materials: the datasets used and/or analyzed during the current study are available from the corresponding author on reasonable request.

Received: 21 August 2024.

Accepted: 22 January 2025.

This work is licensed under a Creative Commons Attribution-NonCommercial 4.0 International License (CC BY-NC 4.0).

©Copyright: the Author(s), 2025

Licensee PAGEPress, Italy

Dermatology Reports 2025; 17:10125

doi:10.4081/dr.2025.10125

Publisher's note: all claims expressed in this article are solely those of the authors and do not necessarily represent those of their affiliated organizations, or those of the publisher, the editors and the reviewers. Any product that may be evaluated in this article or claim that may be made by its manufacturer is not guaranteed or endorsed by the publisher.

Abstract

Acral lentiginous melanoma (ALM) is an infrequent and often missed subtype of melanoma. Its association with spontaneous vitiligo vulgaris is an exceedingly rare condition. The current study presents a rare case of ALM with spontaneous vitiligo vulgaris after complete resection of the ALM. An 84-year-old male patient presented with multiple white skin lesions on the scalp, neck, trunk, and upper and lower limbs for a three-month duration. One year prior, a diagnosis of ALM was confirmed on histopathological examination with a pathological stage of T4bNxMx. The patient did not receive any treatment until the time of presentation, apart from the surgical removal of the primary tumor. No treatment was advised for the patient's vitiligo vulgaris; only observation was recommended. Clinical diagnosis of vitiligo vulgaris was made based on the association with ALM. A review of the literature reveals that only a limited number of case reports have linked vitiligo to ALM, especially in cases where immunotherapeutic agents were not administered. Melanoma is a notably immunogenic malignancy, provoking both humoral and cellular immune responses directed against cytoplasmic and membrane antigens of melanocytes. It is suggested that normal melanocytes may function as neutral observers and become targets of immune responses directed against melanoma cells, leading to melanoma-associated vitiligo. It occurs more commonly as a consequence of immunologic-based therapeutic interventions or after metastatic melanoma; however, the occurrence of spontaneous vitiligo vulgaris several months following complete surgical removal of ALM is possible.

Introduction

Melanoma is the malignant proliferation of atypical melanocytes. Even though it constitutes less than 5% of all skin cancers, the mortality of 60% of cutaneous malignancies and 0.7% of all cancers is attributed to melanoma.¹⁻³ Acral lentiginous melanoma (ALM) was first introduced by Reed in 1976 as the fourth principal subtype of malignant melanoma. The word "acral" refers to its anatomical locus on the extremities, and "lentiginous" describes the unique radial growth pattern observed upon histopathological examination.⁴ In Caucasian populations, 4-6% of melanoma diagnoses are due to ALM. However, ALM constitutes the most commonly encountered melanoma subtype in people of African or Asian descent.⁵

Vitiligo is categorized into various types based on its clinical area of involvement. Non-segmental vitiligo includes focal vitiligo, which presents as scattered macules in isolated areas; mucosal

vitiligo, affecting mucous membranes like lips and genitals; acrofacial vitiligo, predominantly affecting the extremities and face; vitiligo vulgaris, featuring extensive depigmentation across bilateral surfaces of the body, and universal vitiligo, a severe form covering most of the body's surface area. Segmental vitiligo pertains to unilateral depigmented skin patches restricted to a specific segment of the body. A mixed type of vitiligo is also described when there is an overlap between the two aforementioned types of vitiligo.⁶ While multiple mechanisms may be involved in developing vitiligo, the autoimmune hypothesis is presently regarded as the predominant pathway. In clinical settings, the Koebner phenomenon is an acknowledged primary trigger, characterized by depigmentation often observed in patients at sites of repeated friction, such as the waist, or following traumatic events. This is partly explained by the various factors released due to the damage and the stress response against melanocytes. Specifically, danger-associated molecular patterns (DAMPs) are of particular interest as they are thought to initiate the inflammatory process observed in vitiligo during the active phase. Notably, heat shock protein 70 (HSP70), released from damaged melanocytes, has been found in elevated levels in the skin of vitiligo patients and is closely correlated with active disease.⁷

Inflammation in susceptible skin can result in dendritic cells presenting melanocyte peptides in the afferent lymph nodes. This sequence triggers the development of cytotoxic T cells that specifically target melanocytes, along with the synthesis of autoantibodies against melanocyte antigens by lymphocytes. Various subsets of cytotoxic T cells have been identified in vitiligo patients, specifically targeting melanocyte differentiation antigens such as MART-1 and gp100. Cytotoxic CD8 lymphocytes from vitiligo patients predominantly produce interleukin (IL)-17, tumor necrosis factor- α (TNF- α), and interferon- γ (IFN- γ) when exposed to peptides associated with melanocyte differentiation. In the final stages of melanocyte destruction, IFN- γ appears to be pivotal. Additionally, cytokines such as IL-1 β , IL-2, IL-17, IL-22, IL-23, and IL-33 have been found to be increased in individuals with vitiligo or in mouse models. *In vitro* experiments have shown that these cells possess the ability to destroy epidermal melanocytes in pigmented vitiligo skin. This is regarded as the primary mechanism responsible for the destruction of melanocytes in vitiligo.⁷ Research indicates that individuals without vitiligo can harbor anti-melanocyte T cells. However, these self-reactive T cells typically exhibit an anergic phenotype in unaffected individuals. This suggests the presence of a finely tuned equilibrium between pro- and anti-inflammatory signals, which becomes disrupted in vitiligo. Furthermore, regulatory T cells, a critical subset responsible for moderating immune responses, seem to be reduced in number in patients with vitiligo compared to healthy individuals. In addition, there appears to be a correlation between this decrease in regulatory T cells and disease severity.⁷

The simultaneous occurrence of melanoma and vitiligo within the same individual is, at first glance, a medical paradox, given their opposing pathophysiology: melanoma is characterized by extensive proliferation of aberrant melanocytes in the epidermis. Meanwhile, vitiligo is due to the destruction of skin melanocytes, which presents clinically as depigmentation in a patchy fashion. This demonstrates how the coexistence of these two conditions can be perplexing from a medical standpoint. However, with advances in understanding the immunologic basis of melanoma, attempts to explain this phenomenon have been undertaken.^{8,9}

This phenomenon has been referred to as melanoma-associated vitiligo, melanoma-associated depigmentation, melanoma-associated hypopigmentation, and melanoma-associated leukoderma (MAL). These terms have been used interchangeably in the lit-

erature, with no clear consensus on their similarities or differences, with an estimated incidence of 1.4% to 20%.^{10,11} Vitiligo patches are more commonly observed after treatment or in metastatic melanoma.⁹ The current study uniquely highlights a patient with nonmetastatic ALM, distinguishing it from the other more commonly reported melanoma subtypes, such as superficial spreading melanoma and nodular melanoma,¹² that presented with spontaneous generalized vitiligo at distant sites 12 months after complete surgical resection without receiving immunotherapy, in contrast to the more acknowledged depigmentation that develops after immunotherapy and around the site of the melanoma. This reveals a potential immune response against ALM that may develop over several months to be robust enough to manifest as vitiligo, even after the malignant melanoma cells have been eradicated from the body. This case report was written with a literature review in line with the CaReL Guidelines: A Consensus-Based Guideline on Case Reports and Literature Review (CaReL).¹³

Case Report

Clinical presentation

An 84-year-old male patient presented to Smart Health Tower's dermatology clinic in January 2024 with multiple white skin lesions on the scalp, neck, trunk, and upper and lower limbs, which first started to appear in November 2023. The patient had a history of an ulcerative skin lesion on the left heel that was operated upon one year before, in January of 2023 (Figure 1). At that time, a diagnosis of ALM was confirmed on histopathological examination with a pathological stage of T4bNxMx and free surgical margins. The patient had no family history of vitiligo. Until the presentation, the patient did not receive any other treatment modalities apart from the surgical resection of the primary tumor.

Diagnostic approach

Upon physical examination, the patient looked clinically well and healthy. However, there were multiple bilateral white depigmented/hypopigmented vitiliginous patches on the scalp, face, dorsum of the hands, arms, lower abdomen, and feet, particularly on the left heel surrounding the site of the previously operated ALM (Figure 2). Vitiligo was a clinical diagnosis established in this patient through a comprehensive medical history. The assess-

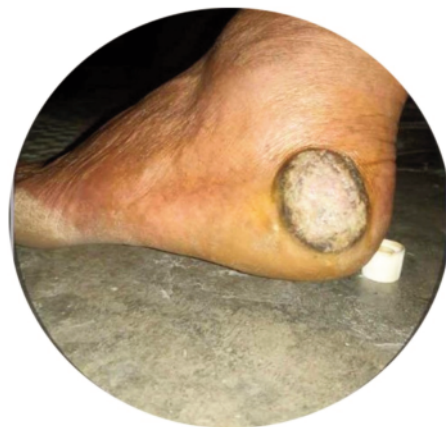

Figure 1. A large ulcerative dark, brown-colored plaque skin lesion with pigmentation at the periphery on the lateral side of the left heel (ALM lesion).

ment included asking about a positive family history or other associated immunologic disorders, despite being negative for these aspects. A thorough clinical examination was conducted, which assessed the distribution and clinical morphology of the depigmented lesions. These lesions were characteristic of vitiligo, presenting as multiple asymptomatic, different-sized, hypopigmented chalky white macules and patches with no redness or changes in skin texture. Some lesions were depigmented, while others exhibited a trichrome color. In addition to that, Wood's light examination was used to narrow down the differential diagnosis, which included progressive macular hypomelanosis, idiopathic guttate hypomelanosis, scleroderma/morphea, and hypopigmented mycosis fungoides. Both detailed history and clinical examinations were based on the exclusion of these conditions. Laboratory blood investigations indicated unremarkable findings with respect to complete blood count, serum electrolytes, and blood film assessments. The erythrocyte sedimentation rate was 2 mm/hr (normal range: <15 mm/hr). The blood urea nitrogen and serum creatinine were 59 mg/dL (normal range: 7-20 mg/dL) and 1.99 mg/dL (normal range: 0.7-1.3 mg/dL), respectively. Erythropoietin level was 9.2 mIU/mL (normal range: 2.6 to 18.5 mIU/mL). Echocardiography was normal. The whole-body positron emission tomography scan also showed no abnormality. Histopathological examination of the previously operated ALM revealed an epidermis with surface ulceration, hyperkeratosis, and parakeratosis. An infiltrative mass exhibited epithelioid spindle

cells with pleomorphic characteristics and a high mitotic rate of 25-38/10 high-power fields, along with melanophages and melanin pigment. The tumor was found in the papillary and reticular dermis, with some areas of subcutaneous infiltration into the dermis (Figure 3). The tumor thickness measured 6.0 mm, with the presence of ulceration, classified as Clark level V due to invasion into the subcutaneous tissue, and the primary tumor staging was T4b. Additionally, lymphovascular and perineural invasions were detected. Both radial and vertical growth phases were observed as well. There was no evidence of tumor necrosis or regression, and the deep and lateral surgical margins were free of tumor involvement. A clinical diagnosis of vitiligo vulgaris was made in association with ALM.

Treatment and follow-up

The patient did not receive immunotherapy after the surgical resection of the ALM due to poor socioeconomic status, which led to difficulty in affording the treatment or the associated costs, such as travel, accommodations, and supportive care, in addition to the lower health literacy. He was untraceable for follow-up until he consulted the dermatologist 12 months later, presenting with vitiligo vulgaris. No treatment was advised for the patient's vitiligo vulgaris; only observation was recommended. However, due to the patient's history of ALM and the pathological stage of the melanoma, he was referred to an oncologist at Hiwa Hospital. They

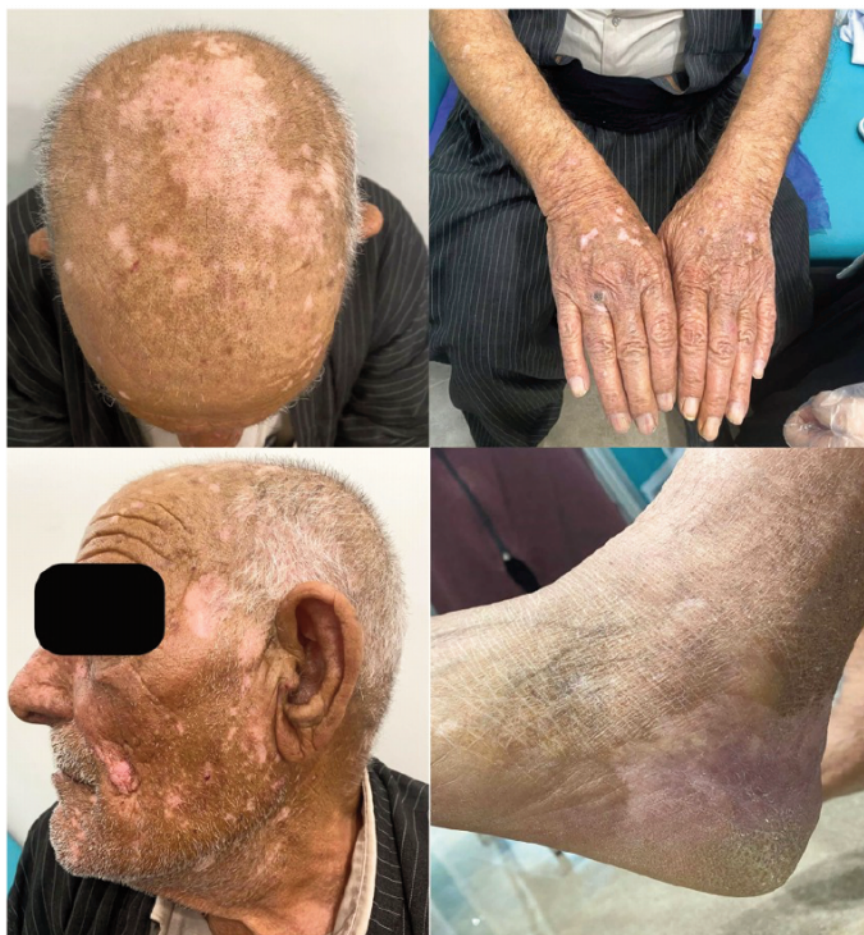

Figure 2. White depigmented/hypopigmented vitiliginous patches on the scalp, face, dorsum of the hands and arms, and lateral side of the left heel surrounding the site of the previously operated ALM.

decided to administer immunotherapy with the humanized monoclonal antibody pembrolizumab (programmed cell death protein 1 [PD-1]/programmed death-ligand 1 [PD-L1]) over a 12-month period with every cycle repeated at 42-day intervals. The first infusion was 400 mg intravenously over 30 minutes, received on February 7, 2024. However, he has received only two infusions so far, with the last one received on May 13, 2024. Despite the patient being non-compliant with immunotherapy, as of the last check-up on June 5, he is overall in good clinical condition with no increase or decrease in size and distribution pattern of the vitiliginous patches. Furthermore, there were no palpable lymph nodes or any signs of melanoma recurrence, and blood investigation parameters were in the normal reference range. Radiological imaging assessment for the patient has not yet been conducted again.

Discussion

A literature review regarding ALM in association with vitiligo revealed a few cases summarized in *Supplementary Table 1*.^{1,9,14-19} Leukoderma, characterized by depigmentation, has been shown in several studies to be increasing in incidence among individuals diagnosed with melanoma. For instance, in a prospective investigation involving 2,954 individuals diagnosed with melanoma at various stages, the prevalence of leukoderma was identified at 2.8%, a notable contrast to the 0.4-2% range observed within the general population.²⁰ However, the incidence ranges from 1.4% to 20% in the genuine literature, which can be explained by the lim-

ited data on this subject and the lack of a proper definition of this condition. For instance, diverse presentations of MAL have been documented in scholarly literature, such as the manifestation of a white halo encircling the melanocytic lesion, recognized as Sutton's nevus, and the development of achromic patches within the scar tissue associated with melanoma.^{9,11,21} In a study by Fouzia *et al.*, depigmentation primarily appeared on the right foot of a patient diagnosed with acral melanoma. However, in uncommon cases, MAL may manifest as depigmented patches distant from the initial lesion.⁹ This was the case for the current patient, who was observed to develop vitiligo lesions 12 months after the surgical removal of the ALM at distant sites.

Certain evidence suggests that MAL exhibits clinical features that set it apart from vitiligo. These distinctive characteristics encompass a later age of onset, lack of a familial history of vitiligo or atopy, an equal prevalence among both genders, the concentration of depigmentation primarily in sun-exposed areas, and the existence of multiple flecked depigmented macules.⁸ Lommerts *et al.* conveyed that a panel of experts conducting blind assessments of photographs featuring 33 patients with vitiligo and 11 patients with MAL inaccurately identified 80% of MAL cases as vitiligo according to clinical manifestation. Consequently, in light of the absence of distinctive discriminative features between the two conditions, the researchers proposed the term "melanoma-associated vitiligo".¹⁰ This condition may exhibit a spontaneous onset preceding or succeeding melanoma initiation; even though melanoma-associated vitiligo after the onset of melanoma encompasses nearly 80% of the cases, it is noteworthy that it may manifest as a premonitory symptom several months to years before the

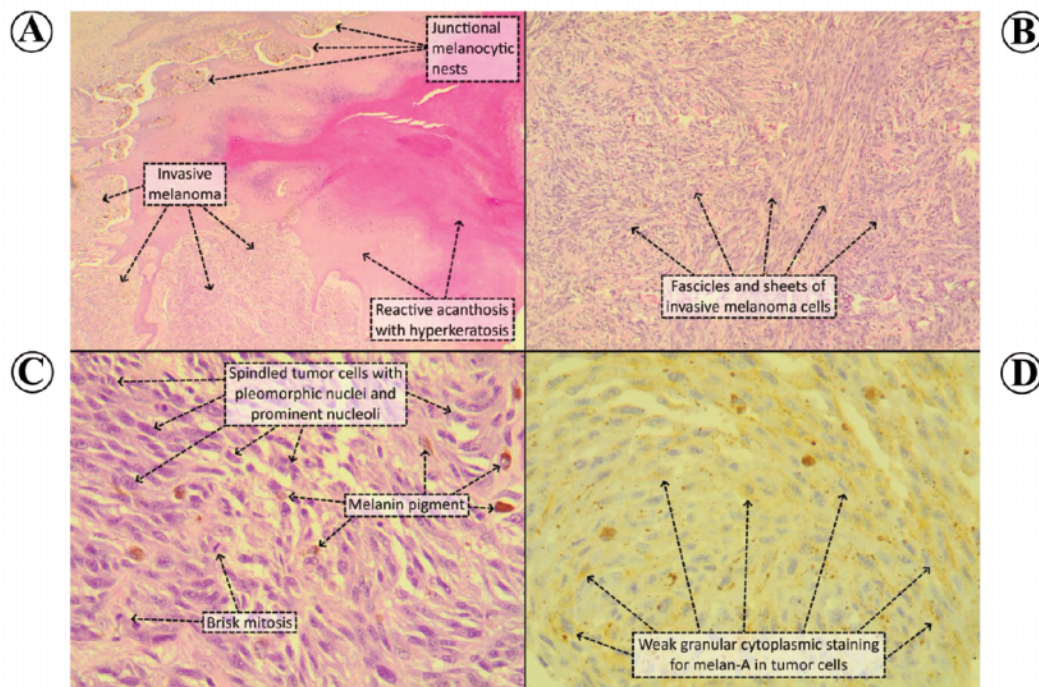


Figure 3. The tumor shows large nests of atypical melanocytes at the dermoepidermal junction with underlying invasive sheets (A). The overlying epidermis exhibits reactive acanthosis with ortho- and parakeratosis. The invasive component consists of sheets and fascicles of spindled tumor cells, displaying both radial and vertical growth phases; tumor thickness and depth of invasion are appreciable, filling an entire 10× field (B). The tumor cells are predominantly spindle-shaped with large, pleomorphic nuclei, vesicular chromatin, irregular nuclear contours, and prominent eosinophilic nucleoli; brisk mitotic activity and melanin pigment deposition are evident (C). Immunohistochemistry for Melan-A shows weak, finely granular cytoplasmic staining (D). Hematoxylin and eosin (A-C); immunohistochemistry for Melan-A using diaminobenzidine (D). Original magnifications: 40× (A), 100× (B), 400× (C,D).

formal diagnosis of the malignancy.⁹

Perhaps one of the possible explanations regarding the distant vitiliginous patches of the present case is that during surgical resection of the ALM, various DAMPs were released into the skin and circulation, which induced a systemic response against the melanocytic antigens throughout the body rather than just a localized response. Although more research is needed to explore this correlation fully, it may be clinically relevant for predicting the development of vitiligo vulgaris in a subgroup of patients undergoing surgical resection of ALM. Embracing the vitiliginous patches as a more robust immune response against malignant melanoma cells with positive prognostic value might also help to reduce the psychological burden experienced by some patients with vitiligo vulgaris.²²

Despite more recent research aimed at better understanding ALM, it is still an understudied disease compared to the other subtypes of melanoma, where several genetic mutations have been identified. For instance, *PTEN*, *KIT*, *BRAF*, and *NRAS* are genes that have been extensively documented as having a crucial role in the pathogenesis of superficial spreading and nodular melanoma subtypes. *BRAF* mutations are identified in approximately half of the cases, and *NRAS* mutations in around 20%. The latter mutation is more frequently detected in skin that has experienced prolonged sun exposure. Nonetheless, *BRAF* mutations have been established in regions subject to minor to no sunlight, such as the mucosal and acral sites. This mutation activates the mitogen-activated protein kinase (MAPK) pathway. The MAPK pathway plays a critical role in melanoma genesis by governing cellular functions such as survival, differentiation, and proliferation. Furthermore, in nearly 10-20% of ALM, mutations within the *KIT* oncogene have been detected. The aforementioned oncogene results in the induction of the phosphoinositide 3-kinase/protein kinase B (PI3K/Akt) in addition to the MAPK pathways via a tyrosine kinase transmembrane receptor. Initially, a hypothesis suggested that trauma could stimulate cutaneous nerves to convert specific cells at their nerve endings into melanomas. However, numerous studies have cast doubt on the association between penetrating injuries and the development of melanomas. Nonetheless, recent studies have suggested a potential association between physical and mechanical stress and the development of melanomas on the foot. Although further research is necessary to establish the causal role of stress and trauma in the development of acral melanoma, this might be a potential shared pathophysiologic explanation for the development of ALM and vitiligo vulgaris in the present case.^{7,22,23}

Melanoma represents a notably immunogenic malignancy, provoking both humoral and cellular responses from the immune system directed against cytoplasmic and membrane antigens of melanocytes.¹¹ Studies have demonstrated an association between malignant melanoma and vitiligo in terms of humoral responses to similar antigens. The Sinclair swine is a distinctive and valuable animal model due to its unique characteristic of being born with malignant melanoma, which undergoes spontaneous regression several weeks after birth, coinciding with generalized depigmentation. The elevation in antibodies directed against antigens predominantly expressed on pigment cells typically occurred before or concurrently with the regression of the tumor and the subsequent loss of pigmentation in that study.¹¹ Furthermore, the enzyme tyrosinase plays a crucial role in melanin synthesis within normal melanocytes and melanoma cells. Therefore, the presence of antityrosinase antibodies in individuals with vitiligo and melanoma suggests a potential autoantigenic role for tyrosinase in these conditions.²⁴ Fishman *et al.* demonstrated that autoantibodies extracted from patients with vitiligo exhibited a deleterious

impact on melanoma cells, evident in both *in vitro* and *in vivo* settings.⁸ There is a suggestion that normal melanocytes might function as neutral observers and become targets of immune responses directed against melanoma cells, leading to their destruction. The CD8⁺ T cells are suggested to have a pivotal role in this context since they have the capability to recognize antigens present in both normal and atypical melanocytes. For instance, tyrosinase, MART-1, gp100, tyrosinase-related protein 2 (TRP-2), and TRP-1/gp75 constitute a subset of identified potential antigens relevant to this context.^{9,25} This immunologic interplay between melanoma and vitiligo is further supported by the action of IL-2, which plays a critical role in fostering the development of antitumor cellular immune responses. This is attributed to its capacity not only to induce the recruitment of cytotoxic and natural killer T cells but also to exert suppressive effects on CD4⁺CD25^{hi}FoxP3⁺ regulatory T cells in individuals diagnosed with metastatic melanoma who exhibit a positive response to the cytokine. Hence, IL-2 amplifies the cytotoxic capabilities of CD8⁺ cells, pivotal in mediating tumor regression and autoimmunity.⁹ In the research conducted by Richards *et al.*, forty-two patients underwent sequential chemo-immunotherapy comprising IL-2, interferon- α 2b, cisplatin, carmustine, and dacarbazine as part of their therapeutic regimen for metastatic melanoma. Out of the thirty-six patients who underwent at least one cycle of therapy, 22 of them demonstrated depigmentation resembling vitiligo, supporting the highly immunogenic basis of melanoma and the potential role of these immune mediators in the development of vitiligo.²⁵

In a study by Wang *et al.*,²⁶ a 67-year-old patient presented with sudden-onset vitiligo vulgaris. Upon thorough physical examination, a palpable lymph node in the inguinal region was detected. Histopathological biopsy revealed metastatic melanoma, in contrast to the current patient, who presented with only a primary, non-metastatic ALM, and the vitiligo developed 12 months later. In another study by Dabbas *et al.*, a 57-year-old patient, who was treated for metastatic ALM by giving nivolumab immunotherapy, developed vitiliginous patches three months after initiating the therapy, and he was advised to continue with the therapy and not receive specific treatment for the vitiligo patches. The development of vitiligo in a patient with ALM is similar to the current case. Still, it is worth mentioning that receiving the immunotherapeutic agent could have been the culprit of inducing the vitiligo development, in contrast to the spontaneous development in the current case.¹ Another interesting case reported by Zheng *et al.* reported a 67-year-old female who presented with spontaneous vitiligo. A year after vitiliginous patches appeared, the patient was found to have malignant melanoma; it is worth mentioning that the patient lived for more than seven years, suggesting prognostic implications for vitiligo in patients with malignant melanoma.¹⁹

The prognostic implications of the correlation between melanoma and vitiligo are particularly intriguing. Despite a higher prevalence of metastatic disease in patients with melanoma-associated vitiligo compared to those with melanoma of equivalent Breslow thickness, these patients demonstrate superior overall survival. Moreover, an increased 5-year survival rate has been reported in comparison with stage-matched melanoma patients without the associated depigmentation.⁹ However, the enhanced antitumor immune response observed in melanoma-associated vitiligo appears insufficient to substantially increase the likelihood of spontaneous and complete eradication of malignant melanoma.¹¹ One of the limitations of the current study is the lack of cytokine measurement and immunological parameters for the current patient, since the clinical management at the time of diagnosis focused primarily on establishing the diagnosis and initiating treatment based on standard clinical

criteria without immediate indication for cytokine or immunological profiling.²⁷ This study advocates for clinicians to recognize such phenomena in clinical practice and encourages the view that vitiligo presented in this way does not need direct treatment; instead, it should be regarded as a positive prognostic factor for the affected patients. Moreover, it underscores that conducting a more comprehensive investigation into cytokines and immunological parameters in these patients could enhance the comprehension of this phenomenon and the immunological underpinnings of both conditions. This exploration may pave the way for novel therapeutic strategies.

Conclusions

Melanoma-associated vitiligo occurs more commonly as a consequence of immunologic-based therapeutic interventions or after metastatic melanoma; however, the occurrence of spontaneous vitiligo vulgaris several months following complete surgical removal of ALM is possible.

References

- Dabbas D, Neema S, Pathak N. Nivolumab induced vitiligo-like depigmentation in metastatic acral lentiginous melanoma. *Pigment Int* 2019;6:105-8.
- Schadendorf D, van Akkooi AC, Berking C, et al. Melanoma. *Lancet* 2018;392:971-84.
- Ahmed R, Sharif D, Jaf M, Amin DM. Effect of TNF- α -308G/A (rs1800629) promoter polymorphism on the serum level of TNF- α among Iraqi patients with generalized vitiligo. *Clin Cosmet Invest Dermatol* 2020;8:25-35.
- Phan A, Touzet S, Dalle S, et al. Acral lentiginous melanoma: a clinicoprognostic study of 126 cases. *Br J Dermatol* 2006;155:561-9.
- Goydos JS, Shoen SL. Acral lentiginous melanoma. *Melanoma* 2016;321-9.
- Ezzedine K, Lim HW, Suzuki TA, et al. Revised classification/nomenclature of vitiligo and related issues: the Vitiligo Global Issues Consensus Conference. *Pigment Cell Melanoma Res* 2012;25:E1-3.
- Speeckaert R, van Geel N. Vitiligo: an update on pathophysiology and treatment options. *Am J Clin Dermatol* 2017;18:733-44.
- Failla CM, Carbone ML, Fortes C, et al. Melanoma and vitiligo: in good company. *Int J Mol Sci* 2019;20:5731.
- Fouzia H, Amal K, Sarah B, et al. Melanoma Associated Leukoderma: Case Series and Literature Review. *Am J Clin Med Res* 2022;10:36-41.
- Lommerts JE, Teulings HE, Ezzedine K, et al. Melanoma-associated leukoderma and vitiligo cannot be differentiated based on blinded assessment by experts in the field. *J Am Acad Dermatol* 2016;75:1198-204.
- Arpaia N, Cassano N, Vena GA. Regressing cutaneous malignant melanoma and vitiligo-like depigmentation. *Int J Dermatol* 2006;45:952-6.
- Markovic SN, Erickson LA, Rao RD, et al.; Melanoma Study Group of the Mayo Clinic Cancer Center. Malignant melanoma in the 21st century, part 1: epidemiology, risk factors, screening, prevention, and diagnosis. *Mayo Clin Proc* 2007;82:364-80.
- Prasad S, Nassar M, Azzam AY, et al. CaReL Guidelines: A Consensus-Based Guideline on Case Reports and Literature Review (CaReL). *Barw Med J* 2024;2:13-19.
- Kim YJ, Lee JB, Kim SJ, et al. Amelanotic acral melanoma associated with KIT mutation and vitiligo. *Ann Dermatol* 2015;27:201-5.
- Edmondson LA, Smith LV, Mallik A. Nivolumab-induced vitiligo in a metastatic melanoma patient: A case report. *J Oncol Pharm Pract* 2017;23:629-34.
- Spring IR, de Wet J, Jordaan HF, et al. Complete spontaneous regression of a metastatic acral melanoma with associated leukoderma. *JAAD Case Rep* 2017;3:524-8.
- Ranaivo IM, Sendrasoa FA, Andrianarison M, et al. Vitiligo Associated with Melanoma in a Malagasy Woman. *Case Rep Dermatol Med* 2019;2019:7925785.
- Deoghare S, Kumar A, Deora MS. An unusual case of acral lentiginous melanoma with leukoderma. *Pigment Int* 2021;8:52-4.
- Zhao E. A Metastatic Melanoma Patient with Spontaneous Melanoma-Associated Vitiligo Survived for up to 7 Years and 5 Months: A Case Report. *Ann Clin Med Case Rep* 2022;8:1-5.
- Quaglino P, Marengo F, Osella-Abate S, et al. Vitiligo is an independent favourable prognostic factor in stage III and IV metastatic melanoma patients: results from a single-institution hospital-based observational cohort study. *Ann Oncol* 2010;21:409-14.
- Abdullah HO, Abdalla BA, Kakamad FH, et al. Predatory Publishing Lists: A Review on the Ongoing Battle Against Fraudulent Actions. *Barw Med J* 2024;2:26-30.
- Jung HJ, Kweon SS, Lee JB, et al. A clinicopathologic analysis of 177 acral melanomas in Koreans: relevance of spreading pattern and physical stress. *JAMA Dermatol* 2013;149:1281-8.
- Minagawa A, Omodaka T, Okuyama R. Melanomas and mechanical stress points on the plantar surface of the foot. *New Engl J of Med* 2016;374:2404-6.
- Buljan M, Šitum M, Lugović L, Vučić M. Metastatic melanoma and vitiligo: a case report. *Acta Dermatovenerol Croat* 2006;14:100-3.
- Daneshpazhooh M, Shokoohi A, Dadban A, Raafat J. The course of melanoma-associated vitiligo: report of a case. *Melanoma Res* 2006;16:371-3.
- Wang JR, Yu KJ, Juan WH, Yang CH. Metastatic malignant melanoma associated with vitiligo-like depigmentation. *Clin Exp Dermatol* 2009;34:209-11.
- Nakamura Y, Fujisawa Y. Diagnosis and management of acral lentiginous melanoma. *Curr Treat Options Oncol* 2018;19:1.