

Autosomal recessive woolly hair/hypotrichosis with homozygous mutation in the *LIPH* gene: a case report

Khalid Alwunais, Jamal Alqahtani, Abdullah Aljalfan, Hadeel Alotaibi

Dermatology Department, College of Medicine, Imam Abdulrahman Bin Faisal University, Dammam, Saudi Arabia

Abstract

Autosomal recessive woolly hair/hypotrichosis (ARWH/H) is a hereditary hair disorder characterized by sparse, short, and curly hair. Mutations in the *Lipase H* (*LIPH*) gene, *LPAR6*, or other genes cause this hereditary hair condition. We report a case of an 11-month-old Saudi boy who presented to our dermatology clinic at King Fahad University Hospital in Al-Khobar (Saudi Arabia) with short, non-growing hair since birth. DNA sequencing revealed a homozygous mutation in the *LIPH* gene at c.280_369dup. Our patient was diagnosed with ARWH/H resulting from a homozygous mutation in *LIPH*.

Key words: hypotrichosis; *Lipase H*; woolly hair; autosomal recessive.

Correspondence: Abdullah Aljalfan, Department of Dermatology, King Fahd University Hospital, 34246 Al Khobar, Saudi Arabia.
E-mail: A.jalfan7@hotmail.com. Tel: +966558744844.

Introduction

Autosomal recessive woolly hair/hypotrichosis (ARWH/H) (OMIM #278150/604379) is a rare hereditary hair shaft disorder characterized by tightly curled hair at birth that only reaches a few centimeters long.¹ This disorder is linked to a mutation in *Lipase H* (*LIPH*) genes, *LPAR6* (*P2RY5*), or other genes.¹ The *LIPH* gene encodes a membrane-associated phosphatidic acid-preferring phospholipase A1, which produces lysophosphatidic acid from phosphatidic acid.^{1,2} *LIPH* is abundantly expressed in hair follicles, contributing significantly to the growth of human hair.² This case report describes an 11-month-old Saudi boy with ARWH/H caused by a mutation in the *LIPH* gene.

Case Report

An 11-month-old Saudi boy presented to our dermatology clinic at King Fahad University Hospital in Al-Khobar, Saudi Arabia. The primary concern was the presence of short, non-growing hair since birth. The mother mentioned that she shaved his hair once after birth, and since then, his hair has remained very fine and thin. The mother also witnessed him gradually losing his eyebrow hair. The patient was born at 37 weeks of gestation via an uneventful vaginal delivery. He was feeding well, and his overall development was within normal limits. The parents were non-consanguineous. His two older siblings exhibited normal hair characteristics, and no similar hair abnormalities had been reported in the maternal or paternal family history.

Upon examination, the scalp showed diffuse hair thinning ranging in length between 0.5 and 1 cm, with wide spaces of baldness and minimal woolly appearance with no primary or secondary skin

lesions (Figure 1). His eyebrows were very thin, while his eyelashes were unaffected. General examination revealed average stature (height and weight were within the normal standard deviation), no dysmorphic features, normally appearing palms and soles, no keratoderma, and normal nails and teeth. Routine investigation was normal, including complete blood count, thyroid, liver, and renal function tests, vitamin D level, and urine analysis. Since both parents exhibited normal hair growth and in the absence of other abnormalities, a diagnosis of nonsyndromic hereditary hypotrichosis was suspected. Direct sequencing was therefore performed, revealing a homozygous variant c.280_369dup (p.Gly94_Lys123dup) in exon 2 of the *LIPH* gene. The clinical and genetic findings confirmed the diagnosis of ARWH/H resulting from a homozygous mutation in *LIPH*. To our knowledge, there have been no reports of cases of *LIPH* homozygous variant c.280_369dup (p.Gly94_Lys123dup) causing hypotrichosis in the Saudi population.

Discussion

The discovery of woolly hair was first made by Gossage in 1907 in a European family.³ Woolly hair is identified as tight curly hair with an average diameter of 0.5 cm and is rarely found in non-Black individuals.^{3,4} Autosomal recessive hypotrichosis is a rare hereditary disorder that can be either syndromic or non-syndromic. It is characterized by abnormal hair growth, with hair typically not growing beyond 2-5 cm, and is usually present at birth or in the first few months of life. Only a few cases of autosomal recessive hypotrichosis have been reported in Saudi Arabia.^{1,5}

The phenotype of the disease differs from one individual to another; some individuals have hypopigmented hair, while others have sparse hair that extends beyond the scalp and involves the eye-

Case Report

brows, eyelashes, axilla, and the rest of the body.^{1,6} The previously reported cases were identified and summarized in Table 1.^{1,5-17}

A literature review suggested that most cases are prevalent in Japan and Pakistan, with few cases reported in Saudi Arabia, Korea, India, Bangladesh, and the Volga-Ural region of Russia. Most

hypotrichosis occurred on the scalp; however, in some cases, the eyebrows, eyelashes, and axilla were also involved. Woolly hair was observed in most of the cases. All reported cases in Japan implicated mutations in the *LIPH* gene, specifically the c.736T>A (p.Cys246Ser) variant, as the causative factor,⁶⁻⁹ while in Pakistani

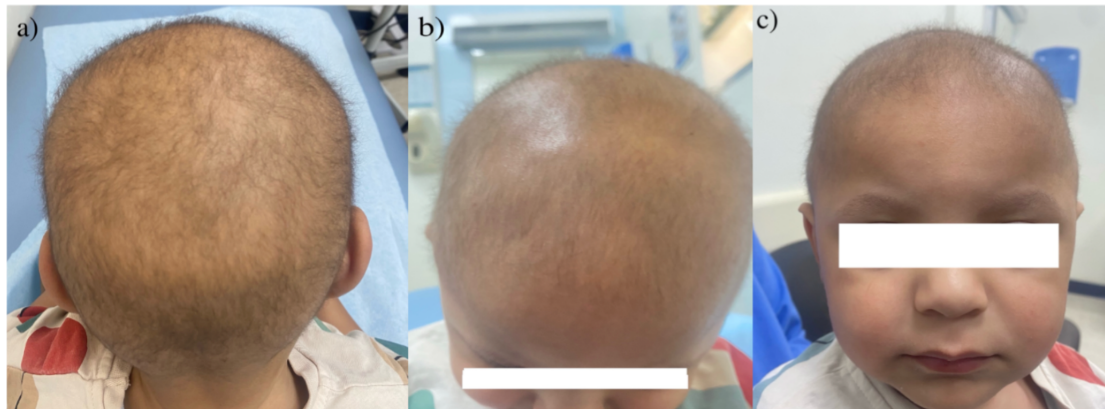


Figure 1. a, b) Clinical features of the patient's hair characterized by diffuse thinning and a mild woolly appearance; c) thinning of the eyebrow.

Table 1. Summary of the clinical data on reported cases of autosomal recessive hypotrichosis.

Reference	Patients (n)	Gene	Mutation	Hypotrichosis	Woolly hair	Origin
Alsharif <i>et al.</i> ¹	1	<i>LPAR6</i>	Homozygous variant (c.373_374delAA)	Scalp	No	Saudi Arabia
Alaboud <i>et al.</i> ⁵	2	N/A	N/A	Scalp, axilla	Yes	Saudi Arabia
Harada <i>et al.</i> ⁶	2	<i>LIPH</i>	Homozygous variant (c.736T>A, p.Cys246Ser)	Scalp, eyebrows	Yes	Japan
Minakawa <i>et al.</i> ⁷	1	<i>LIPH</i>	Homozygous variant (c.736T>A; p.Cys246Ser)	Scalp	Yes	Japan
Shimomura <i>et al.</i> ⁸	3	<i>LIPH</i>	Patient 1: compound heterozygous for (c.736T>A, p.C246S) and (c.742C>A, p.H248N) Patients 2 and 3: homozygous (c.736T>A, p.C246S)	Scalp, eyebrows, eyelashes	Yes	Japan
Matsuno <i>et al.</i> ⁹	1	<i>LIPH</i>	Homozygous variant (c.736T>A, p.Cys246Ser)	Scalp	Yes	Japan
Jelani <i>et al.</i> ¹⁰	11	<i>LIPH</i> <i>DSG4</i> <i>LAH3</i>	Homozygous variant (c.659-660delTA) in <i>LIPH</i> eyelashes, eyebrows, axilla	Scalp,	Yes	Pakistan
Khan <i>et al.</i> ¹¹	114	<i>LIPH</i> <i>LPAR6</i>	Homozygous variant (p.Trp108Arg, p.Ile220ArgfsX29) in <i>LIPH</i> , and (p.Phe24HisfsX28, p.Asp63Val, p.Gly146Arg, p.Ile188Phe) in <i>LPAR6</i>	Scalp, eyebrows, eyelashes, axilla, rest of the body	Yes	Pakistan
Shimomura <i>et al.</i> ¹²	6 families	<i>LPAR6</i>	ARWH2: 69insCATG ARWH18: 172-175delAACT; 177delG ARWH15: 188A4T ARWH5, ARWH24: 562A4T ARWH16: 565G4A	Scalp	Yes	Pakistan
Tariq <i>et al.</i> ¹³	21	<i>LIPH</i>	Family 1: homozygous (c.778A.T, p.Arg260X) Family 2: homozygous (c.322T.C, p.Trp108Arg) Family 3: homozygous (c.659_660delTA, p.Ile220ArgfsX29) Family 4: homozygous (c.659_660delTA, p.Ile220ArgfsX29) Family 5: homozygous (c.280_369dup, p.Gly94_Lys123dup)	Scalp, eyebrows, eyelashes, rest of the body	Families 1-3: No Families 4, 5: Yes	Pakistan
Faruk <i>et al.</i> ¹⁴	1	N/A	N/A	Scalp	No	Bangladesh
Jabeen <i>et al.</i> ¹⁵	1	N/A	N/A	Scalp, axilla	Yes	India
Choi <i>et al.</i> ¹⁶	2	N/A	N/A	Scalp	Yes	Korea
Zemov <i>et al.</i> ¹⁷	119	Group 1 (hypotrichosis 7 phenotype): <i>LIPH</i> Group 2 (hypotrichosis with WH): <i>KRT25</i>	Group 1: homozygous deletion in exon 4 Group 2: homozygous (c.712G>T; p.(Val238Leu))	Scalp	Group 1: No Group 2: Yes	Chuvash and Mari

LPAR6, Lysophosphatidic Acid Receptor 6; N/A, not applicable; *LIPH*, Lipase H; *DSG4*, desmoglein 4; *LAH3*, Localized Autosomal Recessive Hypotrichosis 3; ARWH, autosomal recessive woolly hair; WH, wolly hair.

populations, both *LIPH* and *P2RY5* were found in genotyping with a variety of mutations.¹⁰⁻¹³ Al Aboud *et al.*¹ reported two sisters in Saudi Arabia with ARWH/H. Both sisters exhibited curly, sparse hair on their scalps and in their axillae, although their body hair appeared normal. The only family member known to have curly hair was the father, and the parents were non-consanguineous. The diagnosis was based on clinical findings and family history; no genotyping was done for the parents and patients. Alsharif *et al.*⁵ reported a 5-year-old Saudi girl from the western province who presented with short, sparse hair ranging in length from 3 to 5 cm since birth; However, the eyebrows, eyelashes, and body hair appeared normal. Whole-exome sequencing was performed to detect the *LPAR6* (*P2RY5*) gene with a missense mutation c.373_374delAA. No similar cases were reported on either the father's or the mother's side. All reported cases showed no signs of cognitive impairment, dysmorphic features, or extracutaneous manifestations, except one case that presented with dextrocardia and *situs inversus*.¹⁴ Routine tests, including complete blood count, liver and renal function tests, urine analysis, and thyroid function test, revealed no abnormalities in most cases. As mentioned, *LIPH* synthesizes lysophosphatidic acid, which is an extracellular mediator of many biological functions, and it has a key role in hair epithelial cells that protect against catagen induction by activating mitogen-activated protein kinase/extracellular signal-regulated kinase, thus promoting human hair growth.²

Conclusions

We present the first reported case of ARWH/H in the Saudi population due to a homozygous mutation in the *LIPH* gene at c.280_369dup. This case does not exhibit the classic woolly hair phenotype typically associated with ARWH/H. This may be attributed to the extremely fine and sparse nature of the hair, which could obscure the characteristic woolly texture.

References

1. Al Aboud K, Al Aboud D. Autosomal recessive hypotrichosis simplex with woolly hair: a report of a new family. *Dermatol Reports* 2011;3:e13.
2. Takahashi T, Kamimura A, Hamazono-Matsuoka T, et al. Phosphatidic acid has a potential to promote hair growth in vitro and in vivo and activates mitogen-activated protein kinase/extracellular signal-regulated kinase in hair epithelial cells. *J Invest Dermatol* 2003;121:448-56.
3. Gossage AM. The inheritance of certain human abnormalities. *Eugen Rev* 1912;4:147-53.
4. Mohr OL. Woolly hair a dominant mutant character in man. *J Hered* 1932;23:345-52.
5. Alsharif O, Ahmed AA, Alali AM, Kaki AA. Unusual Clinical Presentation of Autosomal Recessive Woolly Hair. *Skin Appendage Disord* 2020;6:120-2.
6. Harada K, Inozume T, Kawamura T, et al. Two cases of autosomal recessive woolly hair with *LIPH* gene mutations. *Int J Dermatol* 2013;52:572-4.
7. Minakawa S, Matsuzaki Y, Higashino T, et al. Case report: Exploring autosomal recessive woolly hair: genetic and scanning electron microscopic perspectives on a Japanese patient. *Front Med (Lausanne)* 2024;11:1374222.
8. Shimomura Y, Ito M, Christiano AM. Mutations in the *LIPH* gene in three Japanese families with autosomal recessive woolly hair/hypotrichosis. *J Dermatol Sci* 2009;56:205-7.
9. Matsuno N, Kunisada M, Kanki H, et al. A case of autosomal recessive woolly hair/hypotrichosis with alternation in severity: deterioration and improvement with age. *Case Rep Dermatol* 2013;5:363-7.
10. Jelani M, Wasif N, Ali G, et al. A novel deletion mutation in *LIPH* gene causes autosomal recessive hypotrichosis (LAH2). *Clin Genet* 2008;74:184-8.
11. Khan S, Habib R, Mir H, et al. Mutations in the *LPAR6* and *LIPH* genes underlie autosomal recessive hypotrichosis/woolly hair in 17 consanguineous families from Pakistan. *Clin Exp Dermatol* 2011;36:652-4.
12. Shimomura Y, Wajid M, Petukhova L, et al. Mutations in the lipase H gene underlie autosomal recessive woolly hair/hypotrichosis. *J Invest Dermatol* 2009;129:622-8.
13. Tariq M, Azhar A, Baig SM, et al. A novel mutation in the Lipase H gene underlies autosomal recessive hypotrichosis and woolly hair. *Sci Rep* 2012;2:730.
14. Faruk SMR, Kamal SMB, Rahman S. A Case of Woolly Hair with Dextrocardia and Situs Inversus ("Faruk's Syndrome"). *Clin Res Dermatol* 2019;2:1-4.
15. JabeenM, Kaur G, Sharma E, Dogra D. Twisted tressess: a rare case series of familial woolly hair. *Int J Contemp Pediatr* 2022;9:202-4.
16. Choi SI, Lee SY. An unusual case of korean brother and sister with woolly hair. *Ann Dermatol* 2012;24:474-5.
17. Zernov NV, Skoblov MY, Marakhonov AV, et al. Autosomal Recessive Hypotrichosis with Woolly Hair Caused by a Mutation in the Keratin 25 Gene Expressed in Hair Follicles. *J Invest Dermatol* 2016;136:1097-105.

Received: 4 November 2024; Accepted: 26 January 2025.

Conflict of interest: the authors have no conflict of interest to declare.

Ethics approval and consent to participate: no ethical committee approval was required for this case report by the department because this article does not contain any studies with human participants or animals. Voluntary, informed, and written consent was obtained from the patient's parents.

Consent for publication: the patient's parents gave written consent to use personal data for the publication of this case report and any accompanying images.

Availability of data and materials: all data underlying the findings are fully available.

Acknowledgments: the authors thank the patient's guardians for agreeing to the publication of the case details in this manuscript.

Publisher's note: all claims expressed in this article are solely those of the authors and do not necessarily represent those of their affiliated organizations, or those of the publisher, the editors and the reviewers. Any product that may be evaluated in this article or claim that may be made by its manufacturer is not guaranteed or endorsed by the publisher.

This work is licensed under a Creative Commons Attribution-NonCommercial 4.0 International License (CC BY-NC 4.0).