

## Acute generalized exanthematous pustulosis triggered by dupilumab

Caterina Mariarosaria Giorgio,<sup>1</sup> Gaetano Licata,<sup>2</sup> Giuseppe Argenziano,<sup>1</sup> Vittorio Tancredi,<sup>1</sup> Anna Balato,<sup>1</sup> Eugenia Veronica Di Brizzi<sup>1</sup>

<sup>1</sup>Dermatology Unit, University of Campania, Naples; <sup>2</sup>Dermatology Unit, San Antonio Abate Hospital, Trapani, Italy

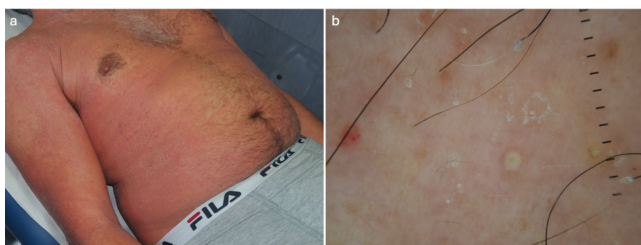
**Key words:** dupilumab; acute generalized exanthematous pustulosis; atopic dermatitis.

Correspondence: Caterina Maria Rosaria Giorgio, MD, Dermatology Unit, University of Campania, via Pansini 5, 80131 Naples, Italy.  
E-mail: caterinagiorgio80@gmail.com

Dear Editor,

We present a rare but clinically significant case of acute generalized exanthematous pustulosis (AGEP) following the administration of dupilumab in a patient with refractory atopic dermatitis (AD). While dupilumab is widely regarded as a safe and effective biologic agent for moderate-to-severe AD across age groups – including adolescents, adults, and increasingly children – emerging reports underscore the need to remain vigilant for uncommon, severe cutaneous reactions. Dupilumab is a fully human monoclonal antibody targeting the interleukin (IL)-4 receptor alpha subunit, thereby inhibiting both IL-4 and IL-13 signaling. It has been approved for use in children, adolescents, and adults with moderate-to-severe AD and has demonstrated strong efficacy and a favorable safety profile (common side effects include conjunctivitis, nasopharyngitis, and injection site reactions) in randomized controlled trials and real-world cohorts alike.<sup>1</sup> Despite this, there have been sporadic reports of paradoxical cutaneous eruptions and psoriasisiform reactions, with AGEP remaining an exceedingly rare adverse event.<sup>2</sup> We report the case of a 49-year-old male with a long-standing history of moderate-to-severe AD who initiated dupilumab therapy after failure of conventional treatments. Two days following the 600 mg loading dose (administered as two 300 mg injections), he developed widespread non-follicular pustules on an erythematous base involving the trunk and upper limbs, associated with fever and systemic discomfort. The patient was hospitalized for further evaluation. Dermoscopic examination revealed multiple well-defined, white pustules on a slightly erythematous background, with fine desquamation and sparse punctate vessels between lesions (Figure 1). Histopathology confirmed a diagnosis of AGEP, showing subcorneal pustules, spongiosis, and a mixed perivascular infiltrate rich in neutrophils and eosinophils. The laboratory profile was notable for leukocytosis in the absence of systemic infection. Treatment consisted of discontinuation of dupilumab and supportive care, including topical corticosteroids and emollients. The patient did not require systemic immunosuppressants. The pustular eruption resolved within two weeks, followed by peripheral desquamation. The patient's underlying AD was later controlled using alternative systemic immunomodulators, as re-

challenge with dupilumab was not considered advisable. AGEP is a severe pustular drug reaction, usually linked to antibiotics (notably beta-lactams), antifungals, and calcium channel blockers.<sup>3</sup> Biologic-induced AGEP is rarely encountered and remains poorly understood. The precise pathophysiological mechanisms by which dupilumab might induce AGEP remain speculative. A plausible explanation may involve cytokine imbalance or immune reprogramming associated with IL-4/IL-13 blockade, triggering an exaggerated neutrophilic skin response in predisposed individuals.<sup>2,3</sup> This hypothesis aligns with recent transcriptomic evidence indicating overlaps between IL-4/IL-13 blockade-induced eruptions and pustular psoriasis.<sup>2</sup> Although a limited number of cases of dupilumab-associated AGEP are available in the literature, comparisons are crucial for contextualizing our report. For instance, Wu *et al.* described a 17-year-old female with AD who developed AGEP after dupilumab exposure.<sup>4</sup> Our case aligns with their observations in terms of timing of onset (within days of initiation), clinical morphology, and resolution post-discontinuation. However, our patient was notably older and did not require systemic corticosteroids, highlighting possible variability in host response and disease course. This case also contributes to the discussion regarding age-related susceptibility. Dupilumab has been approved for pediatric use and has demonstrated excellent tolerability in children and adolescents.<sup>5</sup> However, the occurrence of AGEP in both pediatric and adult patients, albeit rarely, warrants continued surveillance. Physicians prescribing biologics in dermatology should be aware of atypical reactions, especially during the induction phase, and consider AGEP in the differential diagnosis of acute pustular eruptions. Histopathological examination can help distinguish AGEP from other pustular dermatoses such as pustular psoriasis, which may present similarly but differs in distribution, chronicity, and histologic pattern. In summary, while dupilumab remains an essential and generally well-tolerated therapeutic agent for AD in both pediatric and adult populations, clinicians should remain vigilant for the potential development of AGEP. Timely diagnosis and discontinuation of the offending agent are key to favorable outcomes. We hope this report will contribute to the existing literature by reinforcing awareness of this rare adverse event and prompting further research into its underlying mechanisms.



**Figure 1.** a) Clinical presentation of AGEP. The image shows numerous non-follicular pustules predominantly distributed over the trunk and upper extremities. The pustules are set against a background of erythema, with areas of peripheral desquamation, consistent with the resolution phase. b) Dermoscopy reveals multiple well-defined, white pustules on a slightly erythematous background. Fine desquamation is visible between pustules, with sparse punctate vessels near the pustules, suggesting active inflammation.

## References

1. Simpson EL, Paller AS, Siegfried EC, et al. Efficacy and Safety of Dupilumab in Adolescents With Uncontrolled Moderate to Severe Atopic Dermatitis: A Phase 3 Randomized Clinical Trial. *JAMA Dermatol* 2020;156:44-56.
2. Grolleau C, Calugareanu A, Demouche S, et al. IL-4/IL-13 Inhibitors for Atopic Dermatitis Induce Psoriatic Rash Transcriptionally Close to Pustular Psoriasis. *J Invest Dermatol* 2023;143:711-21.e7.
3. Szatkowski J, Schwartz RA. Acute generalized exanthematous pustulosis (AGEP): A review and update. *J Am Acad Dermatol* 2015;73:843-8.
4. Wu L, Ali K, Qiu Y, et al. Dupilumab-induced Acute Generalized Exanthematous Pustulosis in a 17-year-old Female Chinese Patient with Atopic Dermatitis. *Acta Derm Venereol* 2022;102:adv00743.
5. Paller AS, Simpson EL, Siegfried EC, et al; participating investigators. Dupilumab in children aged 6 months to younger than 6 years with uncontrolled atopic dermatitis: a randomised, double-blind, placebo-controlled, phase 3 trial. *Lancet* 2022;400:908-19.

Received: 12 December 2024; Accepted: 20 July 2026.

Conflict of interest: the authors have no conflict of interest to declare.

Ethics approval and consent to participate: no ethical committee approval was required. Informed consent was obtained from the patient included in this study.

Consent for publication: the patient in this manuscript has given written informed consent to publication of his case details and any accompanying images.

Availability of data and materials: all data underlying the findings are fully available.

*Publisher's note: all claims expressed in this article are solely those of the authors and do not necessarily represent those of their affiliated organizations, or those of the publisher, the editors and the reviewers. Any product that may be evaluated in this article or claim that may be made by its manufacturer is not guaranteed or endorsed by the publisher.*

*This work is licensed under a Creative Commons Attribution-NonCommercial 4.0 International License (CC BY-NC 4.0).*