

# Onset of vitiligo following contact dermatitis from eyeliner application in a 20-year-old female

Eugenia Veronica Di Brizzi,<sup>1</sup> Gaetano Licata,<sup>2</sup> Nicola Maria Giorgio,<sup>1</sup> Giuseppe Argenziano,<sup>1</sup> Caterina Mariarosaria Giorgio<sup>1</sup>

<sup>1</sup>Dermatology Unit, Department of Mental and Physical Health and Preventive Medicine, University of Campania “Luigi Vanvitelli”, Naples; <sup>2</sup>Dermatology Unit, San Antonio Abate Hospital, Trapani, Italy

## Abstract

Vitiligo is an autoimmune condition characterized by the destruction of melanocytes, leading to depigmented skin patches. Allergic contact dermatitis, triggered by allergens in cosmetics, can initiate localized immune responses that may progress to systemic immune dysregulation in genetically predisposed individuals. This case explores the potential role of allergic contact dermatitis in triggering vitiligo and proposes mechanisms underlying this association.

Correspondence: Eugenia Veronica Di Brizzi, MD, Dermatology Unit, Department of Mental and Physical Health and Preventive Medicine, University of Campania “Luigi Vanvitelli”, via Pansini, 5, 80131 Naples, Italy.

E-mail: eugeniaveronica.dibrizzi@gmail.com

Key words: vitiligo; eyelid depigmentation; contact dermatitis; Wood’s light examination; cosmetic-induced vitiligo.

Conflict of interest: the authors have no conflict of interest to declare.

Ethics approval and consent to participate: no ethical committee approval was required for this case report by the Department because this article does not contain any studies with human participants or animals. Informed consent was obtained from the patient included in this study.

Consent for publication: the patient provided written informed consent for the publication of her case details and any accompanying images.

Availability of data and materials: all data underlying the findings are fully available.

Received: 12 December 2024.

Accepted: 11 April 2025.

This work is licensed under a Creative Commons Attribution-NonCommercial 4.0 International License (CC BY-NC 4.0).

©Copyright: the Author(s), 2025

Licensee PAGEPress, Italy

Dermatology Reports 2025; 17:10220

doi:10.4081/dr.2025.10220

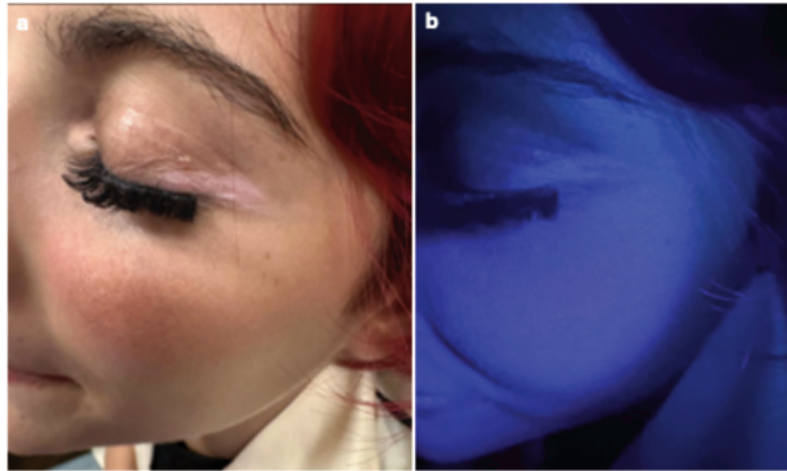
*Publisher's note: all claims expressed in this article are solely those of the authors and do not necessarily represent those of their affiliated organizations, or those of the publisher, the editors and the reviewers. Any product that may be evaluated in this article or claim that may be made by its manufacturer is not guaranteed or endorsed by the publisher.*

## Introduction

A 20-year-old female presented with hypopigmented patches on her upper eyelids following the use of a new eyeliner. Initially, she experienced redness, swelling, and irritation consistent with allergic contact dermatitis, which resolved after discontinuing the product. However, within two weeks, persistent depigmentation developed in the affected areas. Examination confirmed vitiligo through Wood’s light fluorescence, while patch testing revealed positive reactions to paraphenylenediamine (PPD) and nickel, common allergens in cosmetics. This case suggests a possible link between allergic contact dermatitis and the onset of vitiligo, potentially mediated by systemic immune modulation and immune memory sensitization. We hypothesize that the allergic reaction initiated a localized immune response, which evolved into a broader immune dysregulation, unmasking a latent predisposition to vitiligo. The mechanism may involve activation of memory T cells and a “pro-inflammatory microenvironment”, leading to sustained melanocyte destruction. The eyelid area, with its thin skin and heightened permeability, may be particularly susceptible to immune-mediated damage. This phenomenon corresponds with the Koebner effect, wherein localized trauma induces vitiligo in predisposed individuals.<sup>1</sup> This case underscores the importance of patch testing for allergen identification and avoidance in patients with contact dermatitis. It also highlights the need to consider cosmetics as potential contributors to autoimmune conditions like vitiligo. Further studies are warranted to explore the immunological pathways connecting allergic contact dermatitis and vitiligo.

## Case Report

A 20-year-old female presented to the dermatology clinic with well-demarcated hypopigmented patches on her upper eyelids, primarily affecting the lateral canthus and eyelid margins. The patient had started using a new eyeliner approximately one month before symptom onset and reported experiencing immediate redness, swelling, and irritation in the application areas, symptoms consistent with contact dermatitis. These initial reactions subsided after discontinuing the eyeliner, but within two weeks of resolution, the patient noticed persistent depigmentation in the previously affected areas. On physical examination, hypopigmented patches with clear borders were observed on both upper eyelids, while the surrounding skin appeared unaffected, without signs of active inflammation or scaling. The patient reported no pruritus, pain, or systemic symptoms. A Wood’s light examination showed strong fluorescence in the depigmented areas under ultraviolet light, confirming a diagnosis of vitiligo (Figure 1). To further investigate the nature of the initial reaction, patch testing was performed, which revealed positive reactions to paraphenylenediamine (PPD) and nickel, common allergens found in many cosmetic products,



**Figure 1.** a) Clinical examination showing a linear patch of vitiligo on the left upper eyelid, precisely following the pattern where the eyeliner was applied. b) Wood's light examination highlighting the linear vitiligo patch on the left upper eyelid with bright fluorescence, confirming the diagnosis and the extent of depigmentation.

including certain eyeliners. The positive patch test results confirmed that the initial reaction was allergic contact dermatitis rather than a simple irritant response.

## Discussion

Vitiligo is an autoimmune condition characterized by the selective destruction of melanocytes, the pigment-producing cells in the skin. In this case, we hypothesize that the allergic contact dermatitis induced by the eyeliner not only triggered a localized immune response but may have also led to systemic immune modulation, activating a latent predisposition to vitiligo in this specific area. This immune modulation may have created a “pro-inflammatory microenvironment”, sensitizing melanocytes to further immune-mediated destruction, thereby leading to a sustained depigmentation even after the inflammation resolved. Previous studies have documented similar cases where cosmetics, particularly those containing allergens or irritants, have led to the onset of vitiligo.<sup>1,2</sup> Recent studies suggest that non-specific immune pathway activation due to allergic contact dermatitis can contribute to secondary autoimmunity in genetically predisposed individuals.<sup>3,4</sup> Specifically, it is proposed that sensitization to PPD and nickel might activate long-term memory T cells that remain in the skin even after the initial dermatitis resolves. These memory T cells may become reactivated by future immune stimuli, perpetuating an autoimmune attack against melanocytes. Thus, we propose that the role of allergic dermatitis as a trigger for vitiligo is not solely local. Instead, it may act through a form of “immune reprogramming” that promotes immune memory directed against melanocyte antigens. This mechanism could explain why the Koebner phenomenon, commonly associated with physical trauma or acute inflammation, manifested in this case following allergic contact dermatitis. Frequent exposure to cosmetic allergens such as PPD and nickel, commonly found in beauty products, may sensitize immune cells in a way that fosters an environment conducive to melanocyte loss, specifically in areas where cosmetic application occurred.<sup>5</sup> The eyelid area may also be particularly vulnerable due to the thinness and increased permeability of the skin, which can heighten the absorption of allergens and produce a more pronounced immune response than other facial areas. This

vulnerability might play a crucial role in the localization of vitiligo at this sensitive site.<sup>6</sup>

## Conclusions

In summary, this case highlights the importance of considering cosmetic allergens not only as triggers for contact dermatitis but also as potential instigators of autoimmune conditions like vitiligo in predisposed patients. We propose that allergic contact dermatitis can lead to long-term immune modulation through a process of immune memory sensitization. This novel hypothesis suggests a pathophysiological mechanism that warrants further investigation. Patch testing is essential for identifying specific allergens and providing safe alternatives for sensitive patients. Avoiding products containing allergens such as PPD and nickel may reduce the risk of contact dermatitis and, in predisposed individuals, prevent immune-triggered vitiligo.

## References

1. Białczyk A, Welniak A, Kamińska B, Czajkowski R. Oxidative Stress and Potential Antioxidant Therapies in Vitiligo: A Narrative Review. *Mol Diagn Ther* 2023;27:723-39.
2. Ruiz-Villaverde R, Navarro-Triviño FJ. Contact Vitiligo Following Allergic Contact Dermatitis. *Sultan Qaboos Univ Med J* 2022;22:152-3.
3. Lee JH, Ahn BJ, Noh M, Lee AY. Patch test reactions in patients with the additional diagnosis of vitiligo. *Int J Dermatol* 2014;53:187-91.
4. Schallreuter KU, Wood JM, Berger J. Low catalase levels in the epidermis of patients with vitiligo. *J Invest Dermatol* 1991;97:1081-5.
5. Martins C, Migayron L, Drullion C, et al. Vitiligo Skin T Cells Are Prone to Produce Type 1 and Type 2 Cytokines to Induce Melanocyte Dysfunction and Epidermal Inflammatory Response Through Jak Signaling. *J Invest Dermatol* 2022;142:1194-205.e7.
6. Gendler E. Adverse reactions to cosmetics. *Cutis* 1987;39:525-6.