

# Successfully maintained complete remission of mycosis fungoides by umbilical cord blood transplantation: a case report and literature review

Munenari Itoh,<sup>1,2</sup> Sayaka Oshima,<sup>3</sup> Hiroto Ishii,<sup>3</sup> Shingo Yano,<sup>3</sup> Akihiko Asahina,<sup>1</sup> Yoshimasa Nobeyama<sup>1</sup>

<sup>1</sup>Department of Dermatology, The Jikei University School of Medicine, Tokyo; <sup>2</sup>Dermatology Clinic Itoin, Shizuoka; <sup>3</sup>Division of Clinical Oncology and Hematology, Department of Internal Medicine, The Jikei University School of Medicine, Tokyo, Japan

Correspondence: Munenari Itoh, M.D., Ph.D., Department of Dermatology, The Jikei University School of Medicine, 3-25-8 Nishishimbashi, Minato-ku, Tokyo 106-8461, Japan.  
Tel.: +81.3.34331111 - Fax: +81.3.54010125  
E-mail: seaowl@jikei.ac.jp

Key words: mycosis fungoides; hematopoietic stem cell transplantation; umbilical cord blood transplantation; reduced intensity conditioning; myeloablative conditioning.

Contributions: MI, conceptualization, data curation, investigation, resources, and writing-original draft; SO, data curation, writing-review & editing; HI, data curation, investigation, resources, and writing-review and editing; SY, AA, supervision, writing review & editing; YN, conceptualization, supervision, writing review and editing. All authors have read and approved the final version of the manuscript and agreed to be accountable for all aspects of the work.

Conflict of interest: the authors have no conflict of interest to declare.

Ethics approval and consent to participate: no ethical committee approval was required for this case report by the Department, because this article does not contain any studies with human participants or animals. Informed consent was obtained from the patient included in this study.

Consent for publication: the patient gave his written consent to use his personal data for the publication of this case report and any accompanying images.

Availability of data and materials: all data analyzed during this study are included in this published article.

Received: 14 December 2024.

Accepted: 26 March 2025.

This work is licensed under a Creative Commons Attribution-NonCommercial 4.0 International License (CC BY-NC 4.0).

©Copyright: the Author(s), 2025

Licensee PAGEPress, Italy

Dermatology Reports 2025; 17:10222

doi:10.4081/dr.2025.10222

*Publisher's note: all claims expressed in this article are solely those of the authors and do not necessarily represent those of their affiliated organizations, or those of the publisher, the editors and the reviewers. Any product that may be evaluated in this article or claim that may be made by its manufacturer is not guaranteed or endorsed by the publisher.*

## Abstract

Mycosis fungoides (MF) is a major variant of primary cutaneous T-cell lymphoma (CTCL) characterized by infiltration of neoplastic T cells in the epidermis and dermis. This disease progresses gradually and rarely reaches an advanced stage. Once advanced, MF is nearly impossible to treat due to limited therapeutic options. However, allogeneic hematopoietic stem cell transplantation (allo-HSCT) has recently emerged as a potential treatment. Among hematopoietic stem cell (HSC) sources, umbilical cord blood transplantation (UCBT) offers significant advantages. Despite its potential, there are challenges in applying UCBT to adults, and there are only a few reports on its use for MF. We report a Japanese case of advanced MF maintaining complete remission (CR) with UCBT and review previous cases of CTCL, including MF, treated with UCBT.

## Introduction

Mycosis fungoides (MF) is the most common type of cutaneous T-cell lymphoma (CTCL), clinically characterized by an indolent progression over the years from polymorphic patches to plaques to tumors. It predominantly affects the skin, although it may occasionally spread internally in certain instances. Once MF reaches an advanced stage, the prognosis is remarkably poor despite the variety of therapies available. Hematopoietic stem cell transplantation (HSCT) is commonly performed for patients with hematological disorders, making it a promising therapeutic option for advanced MF, with reports of successful outcomes.<sup>1,2</sup>

Umbilical cord blood (UCB) is an alternative but valuable cell source for allogeneic hematopoietic stem cell transplantation (allo-HSCT) when human leukocyte antigen (HLA)-matched related or unrelated donors are not available. Although UCB has a higher non-relapse mortality rate due to poor engraftment and infection compared to bone marrow (BM) and peripheral blood (PB),<sup>3</sup> it offers significant advantages. UCB donors experience less burden at the time of collection. Furthermore, stringent HLA matching is not required in UCB recipients due to the *naïve* immune system of the neonate with maternal-fetal tolerance, resulting in rapid donor adjustment and a lower incidence of severe graft-versus-host disease (GVHD) after transplantation.<sup>4</sup> Taken together, the overall survival rate using UCB is comparable to other cell sources.<sup>3</sup>

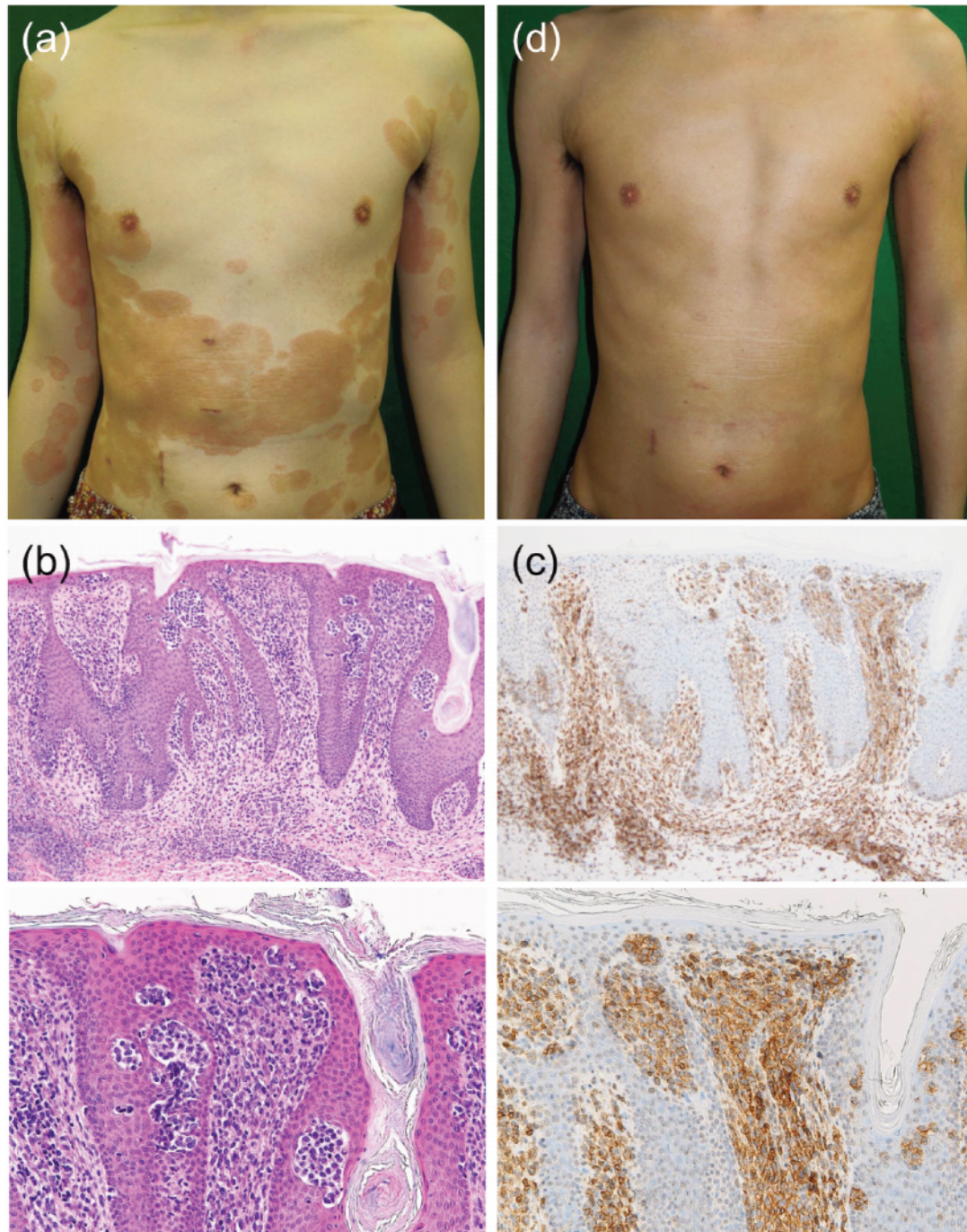
However, UCB has limited applicability to adults because of its low cell count, which can also lead to delayed hematopoietic and immunological recovery. Therefore, umbilical cord blood transplantation (UCBT) is rarely applied for patients with advanced MF. Here, we report a Japanese case of advanced MF maintaining complete remission (CR) with UCBT.

## Case Report

A 35-year-old Japanese man (height: 178 cm, weight: 56 kg) presented with generalized hyperpigmented scaly polymorphic macules (Figure 1a). He had previously undergone narrowband-UVB (NB-UVB) irradiation for the diagnosis of psoriasis, which proved ineffective. Histopathological examination of the skin specimen revealed epidermotropism (Figure 1b) and intradermal

infiltration of atypical CD4<sup>+</sup> T cells (Figure 1c), leading to the diagnosis of MF. A biopsy of the swollen right inguinal lymph node (LN) did not confirm the infiltration of lymphocytes with nuclear atypia. He was started on bexarotene (300 mg) and continued NB-UVB therapy. His skin lesions nearly disappeared and remained controlled for almost 2 years (Figure 1d).

However, an infiltrated nodule appeared on his head and rapidly enlarged (Figure 2a). Since a skin biopsy detected CCR4<sup>+</sup>



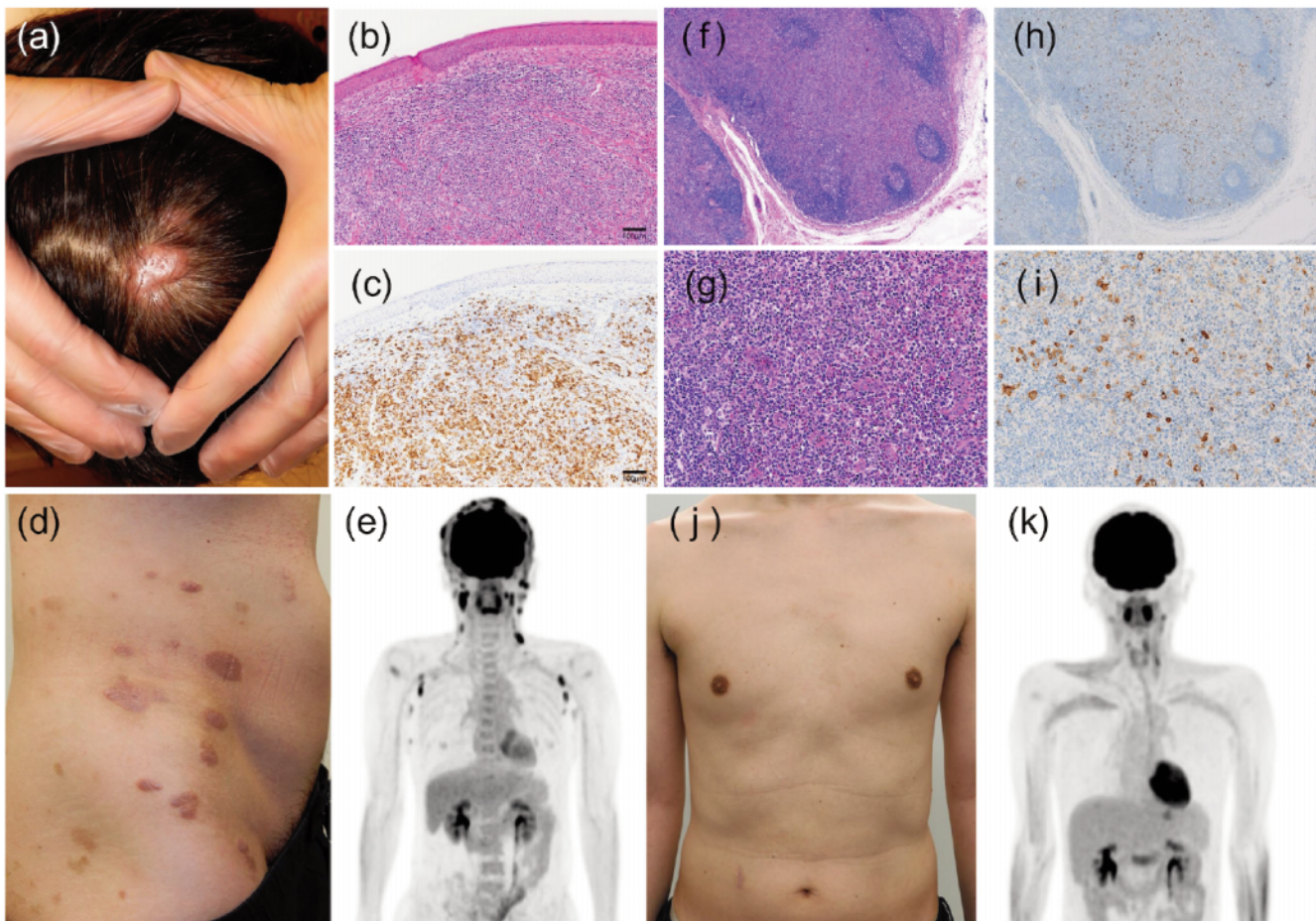
**Figure 1.** Clinical and pathological findings. (a) Hyperpigmented scaly polymorphic macules were spread over the whole body. (b) H&E staining and (c) immunostaining of CD4 antigen of skin specimen. Atypical CD4<sup>+</sup> T cells infiltrated into the dermis, showing epidermotropism (up: low magnification [ $\times 40$ ]; bottom: high magnification [ $\times 200$ ]). (d) The skin lesions had disappeared by bexarotene and NB-UVB irradiation, and temporary remission could be maintained for about two years.

neoplastic T cells (Figure 2 b,c), mogamulizumab was administered for disease regression. Despite eight administrations of mogamulizumab, the disease remained uncontrolled. Additional nodules appeared on his trunk, hip, and genital area (Figure 2d). PET-CT revealed the enlargement of deep internal cervical and axillary LNs (Figure 2e), and cervical LN biopsy showed the infiltration of neoplastic T cells (Figure 2 f,g), indicating stage IIB (T3N2M0B0). Cyclophosphamide, doxorubicin, vincristine, and prednisolone (CHOP) therapy was first chosen for remission induction. It initially demonstrated efficacy, but its effects were not sustained, so brentuximab-vedotin, cyclophosphamide, doxorubicin, and prednisolone (BV-CHP) was twice administered due to the presence of CD30<sup>+</sup> neoplastic T cells in LN (Figure 2 h,i), leading to CR. As CHOP therapy did not maintain a sufficient duration of response, we considered that BV-CHP therapy might eventually fail and that allo-HSCT should be performed while the disease was stable. Due to the absence of a suitable sibling donor and the urgency to perform the transplantation while maintaining CR, allo-HSCT using UCB was pursued. Following myeloablative conditioning (MAC) by cyclophosphamide and total body irradiation (CY/TBI; 12Gy/6Fr), UCBT was performed with one

unit (total nucleated cells:  $2.16 \times 10^7$  cells/kg, CD34<sup>+</sup> cells:  $1.30 \times 10^5$  cells/kg). Mild pre-engraftment immune reactions (PIR) were observed around day 7 post-transplantation. Successful engraftment was confirmed with the neutrophil count exceeding 500 cells/mm<sup>3</sup> on day 15 (white blood cell >1000 cells/mm<sup>3</sup> on day 16, reticulocyte >10% on day 30, platelet > $5 \times 10^4$  mm<sup>3</sup> on day 40). The patient had acute GVHD (overall grade II) in the skin (stage III) and intestinal tract (stage I), which were controlled with immunosuppressive drugs (prednisolone and tacrolimus), and chronic GVHD was not observed. Nearly four years have passed without recurrence of MF, and GVHD is well controlled. The patient continues to be in good overall health (Figure 2 j,k).

## Discussion and Conclusions

Advanced MF has a poor prognosis, even with various treatments, including systemic chemotherapies. Allo-HSCT is emerging as a curative option;<sup>1,2</sup> however, it is challenging to apply to patients with advanced MF since most of them are elderly, making it difficult to find HLA-matched related donors. Conversely,



**Figure 2.** Clinical course leading to UCBT and post-transplantation. (a) A rigid nodule appeared on his head and rapidly enlarged. (b, c) The neoplastic T cells were CCR4<sup>+</sup>, which provided the basis for administration of mogamulizumab, but it was ineffective. (d) The other nodules and plaques appeared on his trunk. (e) PET-CT showed the enlargement of deep internal cervical and axillary lymph nodes. (f, g) Cervical LN biopsy revealed the infiltration of neoplastic T cells (f: low magnification [ $\times 40$ ]; g: high magnification [ $\times 200$ ]). (h, i) Neoplastic T cells in LN were positive against CD30 (h: low magnification [ $\times 40$ ]; i: high magnification [ $\times 200$ ]). (j) A complete remission was achieved after UCBT. (k) PET-CT did not show lymphadenopathy.

UCBT does not require strict HLA matching, facilitating donor availability. However, the small number of cells limits its application to adults, and case reports on this topic are scarce.

There is no clear difference in the outcome of allo-HSCT between MF and acute myeloid leukemia (AML).<sup>1-3,5</sup> Moreover, outcomes of allo-HSCT for hematologic malignancies have been reported to be less dependent on the stem cell source (related or unrelated BM, PB, or UCB),<sup>3,5</sup> although there are some differences based on the type of malignancy. However, the outcome of UCBT for MF has been regrettably poor based on reported cases. The first successful case of UCBT for MF was reported in 2009.<sup>6</sup> In this case, UCBT was performed after a failed allo-HSCT with reduced-intensity conditioning (RIC) from an unrelated donor. However, the patient relapsed and developed a duodenal ulcer due to Epstein-Barr virus-associated lymphoproliferative disease. Consequently, tacrolimus given for GVHD prophylaxis was discontinued, and the recurrence of MF spontaneously improved, which was likely not due to UCBT but to a graft-*versus*-lymphoma effect. Seven other cases of UCBT in patients with MF have been reported, four of which resulted in death,<sup>7-9</sup> while the others experienced recurrence<sup>10</sup> or survived (no detailed description)<sup>11</sup> (Supplementary Table 1). Additionally, there is a case report of successful UCBT in another type of CTCL (primary cutaneous CD8<sup>+</sup> aggressive epidermotropic cytotoxic T-cell lymphoma [PCLAE-CTL]),<sup>12</sup> but the observation period was short, about one year. A previous report suggested that RIC has shown better results than MAC when performing allo-HSCT for patients with MF.<sup>1</sup> Therefore, RIC should be considered to reduce patient burden. However, previously reported MF cases treated with UCBT followed by RIC have resulted in relapse or death,<sup>6,7,9</sup> while in AML cases, even with RIC, the outcomes are comparable.<sup>5</sup> One reason may be that MF is derived from skin-resident effector memory T cell (T<sub>EM</sub>), which is distinct from other lymphomas. Indeed, Clark *et al.* reported that the therapeutic response to alemtuzumab was different in T<sub>EM</sub>-derived MF and central memory T cell (T<sub>CM</sub>)-derived Sézary syndrome, a similar but distinct type of cutaneous lymphoma.<sup>13</sup> Alemtuzumab depletes all circulating T<sub>CM</sub>, both benign and malignant, traveling between the blood and skin, while a diverse T<sub>EM</sub> population persists in the skin. This might also apply to the result of ablative regimens. RIC might potentially leave residual neoplastic skin-homing T cells, thereby increasing the risk of recurrence, especially since T<sub>EM</sub>-derived MF show a strong affinity for the skin.

Additionally, our case received mogamulizumab, a CCR4 antibody that may have suppressed regulatory T cells, which play an important role in the maintenance of immune tolerance after transplantation and activated cytotoxic T cells. Mogamulizumab has been reported to be significantly involved in the development of severe GVHD and increase the risk of GVHD-related mortality, making it advisable to avoid its use prior to transplantation.<sup>14</sup> In our case, the acute GVHD (grade II) that developed was fortunately clinically controllable. However, it is possible that if RIC had been performed instead of MAC, the residual host cytotoxic T cells activated by mogamulizumab would have rejected the few HSCs in the UCB. This might be true for UCBT, where the number of transplanted cells is lower than that in allo-HSCT using other cell sources. Even without the administration of mogamulizumab, this likely necessitates intensive MAC for successfully maintaining CR with UCBT.

Furthermore, outcome-related factors have also been reported to involve disease status at the time of transplantation.<sup>1</sup> In our case, CR was achieved with remission induction therapy using BV-CHP, which may be one of the major factors, unlike in other reported cases. Overall, even with allo-HSCT, outcomes may dif-

fer depending on treatment options, ablative regimen before transplantation, and the type of lymphoma, particularly the cutaneous-derived types.

Nevertheless, HSCT remains a valid therapeutic option for advanced MF, and UCB serves as an important cell source for elderly CTCL patients who have difficulty finding related donors. There are still few case reports, with most originating from Japan, reflecting UCB's limited application in other ethnicities with larger body sizes. Future research needs to gather and analyze worldwide cases of UCBT for CTCL, including MF, to determine optimal conditions and effectiveness, encompassing both successful outcomes and failures.

## References

- Mori T, Shiratori S, Suzumiya J, et al. Outcome of allogeneic hematopoietic stem cell transplantation for mycosis fungoides and Sézary syndrome. *Hematol Oncol* 2020;38:266-71.
- de Masson A, Beylot-Barry M, Ram-Wolff C, et al. Allogeneic transplantation in advanced cutaneous T-cell lymphomas (CUTALLO): a propensity score matched controlled prospective study. *Lancet* 2023;401:1941-50.
- Yano S, Yokoyama H, Yanada M, et al. Role of alternative donor allogeneic hematopoietic stem cell transplantation in patients with intermediate- or poor-risk acute myeloid leukemia in first complete remission. *Bone Marrow Transplant* 2019;54:2004-12.
- Gupta AO, Wagner JE. Umbilical Cord Blood Transplants: Current Status and Evolving Therapies. *Front Pediatr* 2020;8:1-11.
- Peffault de Latour R, Brunstein CG, Porcher R, et al. Similar Overall survival using sibling, unrelated donor, and cord blood grafts after reduced-intensity conditioning for older patients with acute myelogenous leukemia. *Biol Blood Marrow Transplant [Internet]* 2013;19:1355-60. Available from: <http://dx.doi.org/10.1016/j.bbmt.2013.06.006>
- Fukushima T, Horio K, Matsuo E, et al. Successful cord blood transplantation for mycosis fungoides. *Int J Hematol* 2009;88:596-8.
- Tsuji H, Wada T, Murakami M, et al. Two cases of mycosis fungoides treated by reduced-intensity cord blood transplantation. *J Dermatol* 2010;37:1040-5.
- Matsukawa T, Goto H, Takahashi K, et al. A fatal case of cytomegalovirus ventriculoencephalitis in a mycosis fungoides patient who received multiple umbilical cord blood cell transplantations. *Int J Hematol* 2012;95:217-22.
- Nakaike T, Kato K, Oku S, et al. Reduced-intensity conditioning followed by cord blood transplantation in a patient with refractory folliculotropic mycosis fungoides. *Int J Hematol* 2013;98:491-5.
- Pawar R, Kasi Loknath Kumar A, Woodroof J, et al. Skin Recurrence of Transformed Mycosis Fungoides Postumbilical Cord Blood Transplant despite Complete Donor Chimerism. *Case Rep Hematol* 2014;2014:1-5.
- Kaku Y, Otsuka A, Tanizaki H, et al. Dual CD4/CD8-positive ichthyosiform mycosis fungoides with lymph node, peripheral blood and cardiac involvement: A case report. *Acta Derm Venereol* 2016;96:564-5.
- Ichikawa S, Fukuhara N, Hatta S, et al. Successful cord blood stem cell transplantation for primary cutaneous CD8-positive aggressive epidermotropic cytotoxic T-cell lymphoma complicated with cerebral infiltration. *Intern Med* 2018;57:2051-5.

13. Clark RA, Watanabe R, Teague JE, et al. Skin effector memory T cells do not recirculate and provide immune protection in alemtuzumab-treated CTCL patients. *Sci Transl Med* 2012; 4:1-10.
14. Fuji S, Inoue Y, Utsunomiya A, et al. Pretransplantation anti-

CCR4 antibody mogamulizumab against adult T-cell leukemia/lymphoma is associated with significantly increased risks of severe and corticosteroid-refractory graft-versus-host disease, nonrelapse mortality, and overall mortality. *J Clin Oncol* 2016;34:3426-33.

---

*Online Supplementary Material:*

*Supplementary Table 1. Literature review of reported cases of cutaneous T-cell lymphomas treated with UCBT.*