

# Cutaneous complications of cyclosporine: a case of drug-induced folliculitis in atopic dermatitis

Mohammad Al-Haddab,<sup>1</sup> Rema Alkahtani,<sup>1</sup> Faisal BinKhonain,<sup>1</sup> Amany Fathaddin<sup>2</sup>

<sup>1</sup>Dermatology Department; <sup>2</sup>Pathology Department, College of Medicine, King Saud University, King Khalid University Hospital, Riyadh, Saudi Arabia

## Abstract

Cyclosporine-induced folliculitis remains underreported and underrecognized in clinical practice, posing diagnostic challenges for dermatologists and clinicians. In this case report, we present a compelling case of cyclosporine-induced folliculitis. A 40-year-

old patient with severe atopic dermatitis was treated with topical steroids, calcineurin inhibitor, and phototherapy for 6 months. After starting cyclosporine 150 mg, acne-like eruptions appeared, and a 4 mm skin biopsy revealed folliculitis and perifolliculitis. Cyclosporine-induced folliculitis is a rare adverse effect of cyclosporine therapy, requiring prompt management through dose adjustment, discontinuation, and adjunctive therapies.

Correspondence: Mohammad Al-Haddab, Chairman and Consultant Dermatologist, Dermatology Department, College of Medicine, King Saud University, King Khalid University Hospital, Riyadh, Saudi Arabia.

E-mail: malhaddab@gmail.com

Key words: cyclosporine; cyclosporine-induced folliculitis; acneiform eruptions; cutaneous side effects.

Conflict of interest: the authors have no conflict of interest to declare.

Ethics approval and consent to participate: no ethical committee approval was required for this case report by the Department, because this article does not contain any studies with human participants or animals. Informed consent was obtained from the patient included in this study.

Consent for publication: the patient gave his written consent to use his personal data for the publication of this case report and any accompanying images.

Availability of data and materials: all data supporting the findings of this study are included in this case report. Additional details are available from the corresponding author upon reasonable request.

Acknowledgments: this work was supported by the College of Medicine Research Center, Deanship of Scientific Research, King Saud University Medical City, King Saud University, Riyadh, Saudi Arabia.

Received: 28 December 2024.

Accepted: 26 January 2025.

This work is licensed under a Creative Commons Attribution-NonCommercial 4.0 International License (CC BY-NC 4.0).

©Copyright: the Author(s), 2025

Licensee PAGEPress, Italy

Dermatology Reports 2025; 17:10242

doi:10.4081/dr.2025.10242

*Publisher's note: all claims expressed in this article are solely those of the authors and do not necessarily represent those of their affiliated organizations, or those of the publisher, the editors and the reviewers. Any product that may be evaluated in this article or claim that may be made by its manufacturer is not guaranteed or endorsed by the publisher.*

## Introduction

Cyclosporine, a potent immunosuppressive agent, is widely used to manage various autoimmune and inflammatory conditions, including organ transplantation and autoimmune dermatoses.

While its efficacy in controlling immune-mediated diseases is well-established, cyclosporine therapy is associated with a spectrum of adverse effects, ranging from nephrotoxicity to cutaneous manifestations.<sup>1</sup> One dermatological complication is cyclosporine-induced folliculitis, a relatively uncommon adverse reaction characterized by developing inflammatory papules and pustules involving hair follicles.<sup>2</sup> Despite its recognition as a potential side effect of cyclosporine therapy, cyclosporine-induced folliculitis remains underreported and underrecognized in clinical practice, posing diagnostic challenges for dermatologists and clinicians. This case report presents a compelling case of cyclosporine-induced folliculitis, detailing its clinical presentation, histopathological findings, and management approach. By elucidating the nuances of this adverse drug reaction, we aim to enhance awareness and facilitate timely recognition and management of cyclosporine-induced folliculitis among healthcare professionals.

## Case Report

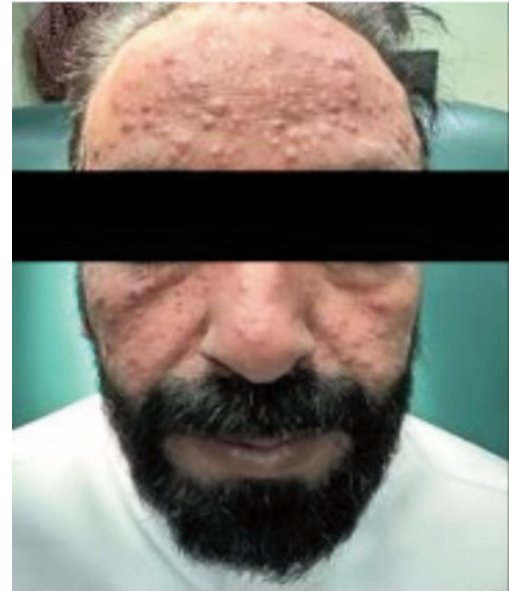
A 40-year-old, medically healthy male presented in our dermatology clinic for severe atopic dermatitis. The patient has been treated with moderate- to high-potency topical steroids, a topical calcineurin inhibitor, and phototherapy for 6 months with minimal response. Consequently, a regimen of cyclosporine at 150 mg twice daily was initiated. Two months later, the patient began to have acne-like eruptions all over the face. Those lesions started suddenly, and they were not itchy or painful. Skin examination showed multiple varying-sized, well-defined, erythematous, infiltrated papules over the face (Figure 1). A 4 mm skin biopsy was taken from a lesion over the forehead, which showed folliculitis and perifolliculitis with mixed dermal infiltrates (Figure 2). The diagnosis of folliculitis was made based on clinical and histological findings. The patient was advised to discontinue cyclosporine and was prescribed a course of clindamycin 150 mg twice daily for two months. At the follow-up visit, the patient showed significant improvement, with fewer papular eruptions compared to baseline (Figure 3).

## Discussion

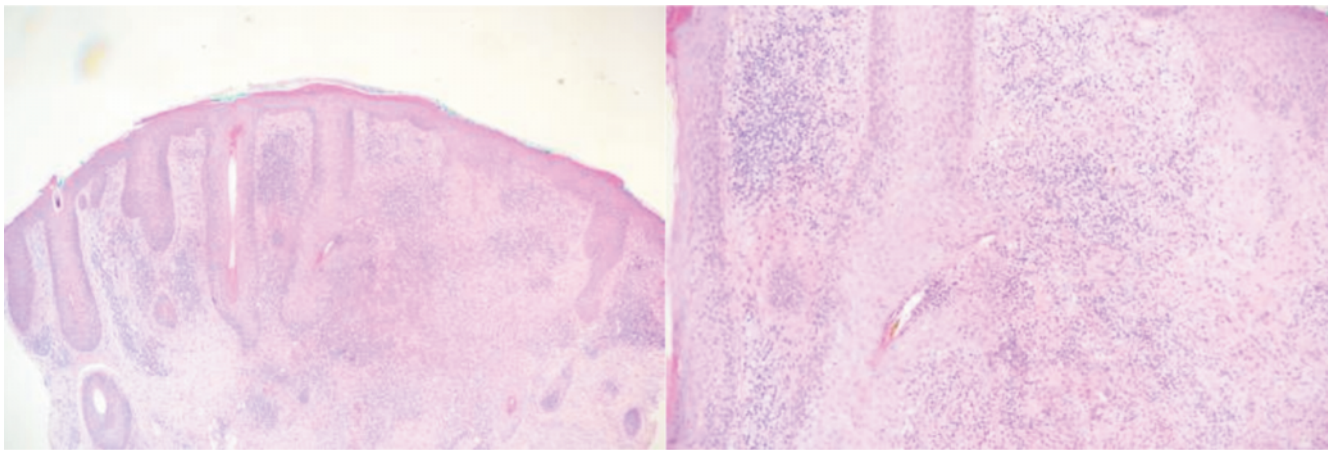
Cyclosporine is a potent immunosuppressant drug with known anti-inflammatory characteristics. Its various clinical applications include use in diverse immuno-dermatological diseases, such as atopic dermatitis, psoriasis, and urticaria.<sup>3</sup>

Cyclosporine was the first immunosuppressive agent found to act selectively on T-cells. Studies have demonstrated that cyclosporine decreases the quantity of helper/inducer T-cells and the number of activated cells that express Interleukin (IL)-2, IL-4, and IL-5. Additionally, it hinders the proliferation and specialization of B-lymphocytes and the operational functions of mononuclear phagocytes, Langerhans cells, and eosinophils. Moreover, a recent immunohistochemistry investigation has demonstrated that cyclosporine may have a therapeutic impact by influencing the cutaneous nerve system through changes in innervation and the expression of neuropeptides in the affected skin of atopic dermatitis. Furthermore, cyclosporine prevents the activation of mast cells (MC) *via* modifying the spatial arrangement between MCs and the nerves in the affected skin, indicating a novel element of cyclosporine's activities in treating disease activity.<sup>4</sup>

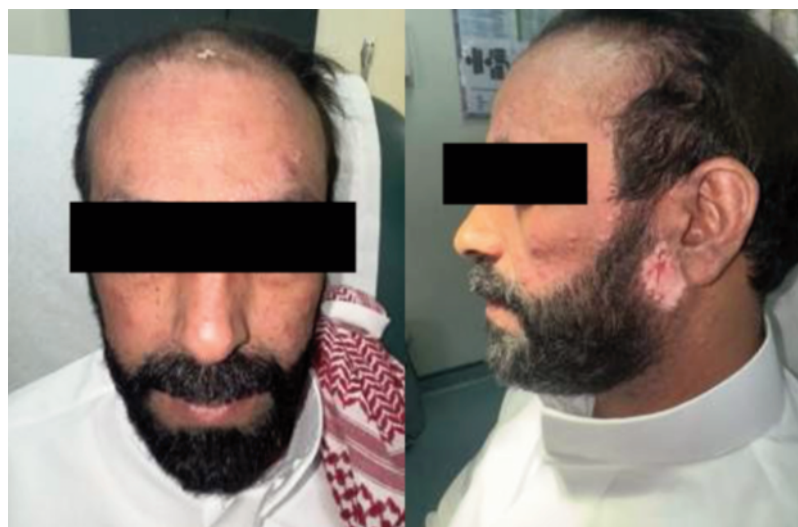Cyclosporine has been approved for the treatment of atopic



**Figure 1.** Clinical appearance before clindamycin treatment.



**Figure 2.** Microscopic section showing marked mixed inflammatory cells, most of which are neutrophils, infiltrating the hair follicle and perifollicular dermis (H&E,  $\times 4$  and  $\times 10$ ).



**Figure 3.** Clinical appearance after clindamycin treatment.

dermatitis in Europe and has been used off-label for the management of various inflammatory skin conditions. Atopic dermatitis is a chronic inflammatory skin condition requiring an interdisciplinary approach encompassing appropriate skin hydration, pharmacological therapy, and identifying and eliminating triggers.

Traditional treatments are ineffective for some patients, necessitating the use of anti-inflammatory and immunosuppressive agents such as cyclosporine, as demonstrated in the present case.<sup>4</sup>

Although infrequent, cyclosporine is associated with undesirable effects that range in severity, including nephrotoxicity, induction and/or deterioration of systemic hypertension, hyperlipidemia, and central nervous system toxicity.<sup>5</sup>

A previous study<sup>6</sup> found that the skin is the primary site of cyclosporine accumulation, and the majority of cyclosporine's cutaneous side effects involve the pilosebaceous unit: hypertrichosis, sebaceous hyperplasia, acne, folliculitis, epidermal cysts, and pilar keratosis.<sup>7</sup> Another study, which treated 67 out of 100 kidney transplant recipients with cyclosporine and methylprednisolone, revealed that 28% of them had cutaneous manifestations related to their previous uremic state. Most of the lesions concerned the pilosebaceous unit: hypertrichosis (60%), epidermal cysts (28%), pilar keratosis (21%), acne (15%), folliculitis (12%), and sebaceous hyperplasia (10%). In our case, the patient only exhibited folliculitis.

In the reported literature, all patients who experienced cutaneous side effects of cyclosporine were immunocompromised; our patient was medically free.

El-Shahawy *et al.* reported a case of a renal transplant patient who developed severe acne with progression to nodulocystic acne (acne conglobata), which only showed resolution 12 months after discontinuing cyclosporine.<sup>5</sup> In our case, we discontinued the use of cyclosporine and we started the patient on a 150-mg dosage of clindamycin for a month, along with topical clindamycin, which resulted in significant improvement with fewer papular eruptions compared to the baseline.

---

## Conclusions

In conclusion, cyclosporine-induced folliculitis is a rare but recognizable adverse effect of cyclosporine therapy. Clinicians should be aware of this potential complication and manage it promptly through dose adjustment, discontinuation, and adjunctive therapies. Continued documentation and reporting of such cases will enhance understanding and guide best practices in managing cyclosporine-associated dermatological side effects.

---

## References

1. Matsuda S, Koyasu S. Mechanisms of action of cyclosporine. *Immunopharmacology* 2000;47:119-25.
2. Hooten JN, Myers SA. Update on Benign and Inflammatory Skin Disease Secondary to Transplant Medication. In: Zwald F, Brown M. (eds) *Advances in Transplant Dermatology*. Springer; 2015.
3. Rajagopalan M, Saraswat A, Chandrashekar B, et al. Role of cyclosporine (CSA) in immuno-dermatological conditions. *Indian Dermatol Online J* 2022;13:585.
4. Dehesa L, Abuchar A, Nuno-Gonzalez A, et al. The use of cyclosporine in dermatology. *J Drugs Dermatol* 2012;11:979-87.
5. El-Shahawy MA, Gadallah MF, Massry SG. Acne: A potential side effect of cyclosporine a therapy. *Nephron* 1996;72:679-82.
6. Bencini PL, Montagnino G, Sala F, et al. Cutaneous lesions in 67 cyclosporin-treated renal transplant recipients. *Dermatology* 1986;172:24-30.
7. Ilyas M, Colegio OR, Kaplan B, Sharma A. Cutaneous toxicities from transplantation-related medications. *Am J Transplant* 2017;17:2782-9.