



Dermatology Reports

<https://www.pagepress.org/journals/index.php/dr/index>

eISSN 2036-7406



Publisher's Disclaimer. E-publishing ahead of print is increasingly important for the rapid dissemination of science. **Dermatology Reports** is, therefore, E-publishing PDF files of an early version of manuscripts that undergone a regular peer review and have been accepted for publication, but have not been through the copyediting, typesetting, pagination and proofreading processes, which may lead to differences between this version and the final one.

The final version of the manuscript will then appear on a regular issue of the journal.

E-publishing of this PDF file has been approved by the authors.

Please cite this article as:

Furudate S, Nakagawa H, Asano Y. Bullous pilomatricoma in young children. Dermatol Rep 2025 [Epub Ahead of Print] doi: 10.4081/dr.2025.10305

 © the Author(s), 2025
Licensee [PAGEPress](https://www.pagepress.org/), Italy

Submitted 22/02/25 - Accepted 20/10/25

Note: The publisher is not responsible for the content or functionality of any supporting information supplied by the authors. Any queries should be directed to the corresponding author for the article.

All claims expressed in this article are solely those of the authors and do not necessarily represent those of their affiliated organizations, or those of the publisher, the editors and the reviewers. Any product that may be evaluated in this article or claim that may be made by its manufacturer is not guaranteed or endorsed by the publisher.

Bullous pilomatricoma in young children

Sadanori Furudate,¹ Haruka Nakagawa,¹ Yoshihide Asano²

¹Department of Dermatology, National Hospital Organization Sendai Medical Center, Sendai;

²Department of Dermatology, Tohoku University Graduate School of Medicine, Sendai, Japan

Correspondence: Sadanori Furudate, Department of Dermatology, National Hospital Organization Sendai Medical Center, 2-11-12 Miyagino, Miyagino-ku, Sendai, Miyagi 983-8520, Japan.

E-mail: s.furudate@derma.med.tohoku.ac.jp

Key words: pilomatricoma; blister formation; young children.

Conflict of interest: the authors have no conflict of interest to declare.

Ethics approval and consent to participate: no ethical committee approval was required for this case report by the Department, because this article does not contain any studies with human participants or animals. Informed consent was obtained from the patients' relatives.

Consent for publication: the patients' relatives provided written informed consent for the publication of this case report and any accompanying images.

Availability of data and materials: the datasets used and analyzed during the current study are available upon reasonable request from the corresponding author.

Dear Editor,

Pilomatricoma is a benign tumor characterized by differentiation from hair matrix cells to hair cortical cells. It commonly occurs on the head and neck in young individuals. Although blistering is rare, when present, it is typically observed on the upper arms, shoulders, and back. The condition is more frequently seen in teenagers and young adults; however, it is rare in young children.

The first case we report (Case 1) involves a 6-year-old Japanese girl who presented to our outpatient clinic with a 6-month history of a tumor on her back. On her initial visit, a physical examination revealed a 25-mm, firm subcutaneous nodule on the left shoulder, with a 20-mm, soft, dome-shaped, erythematous, broad-based pedunculated nodule directly above it (Figure 1A). The lesion was surgically excised. Histologically, basaloid cells and ghost cells were observed in the dermis, consistent with a pilomatricoma. Additionally, extensive capillary hyperplasia was noted in the surrounding area. A densely dilated lumen surrounded by thin endothelial cells was identified overlying the pilomatricoma (Figure 1 B,C). Immunohistochemically, the endothelial cells were predominantly CD34-positive, with some D2-40 positivity and scattered CD31 expression (Figure 1 D-F). Scattered lymphatic duct dilatations were also observed; however, the large luminal-like area directly above the tumor was negative for all markers on immunohistochemistry.

The second case (Case 2) involves a 6-year-old Chinese boy who visited our outpatient clinic with a 3-month history of a tumor on his right upper arm. On his initial visit, a physical examination revealed a 20-mm, firm subcutaneous nodule on the right upper arm, with a 5-mm, soft, dome-shaped, pinkish-red nodule directly above it (Figure 1 G,H). The lesion was surgically excised. Histologically, basaloid cells and ghost cells were observed in the dermis, consistent with a pilomatricoma. In the superficial layer, dilated and edematous lymphatic vessels were identified within the dermis (Figure 1I).

Pilomatricoma with bullous lesions is a relatively rare clinical entity, accounting for only 3-6% of all hair follicle tumors.¹ Most reported cases occur in teenagers and young adults. The most common sites of occurrence are the upper arms, shoulders, and back, with a relatively low incidence on the

face, which is the usual site of pilomatricoma. Possible contributing factors for the higher prevalence in the upper arm and shoulder include frequent physical activity and falls in children, making these areas more susceptible to external forces. The histologic features of the bullous type include ductal dilatation and edema in the dermis directly above the tumor. The lumen in these cases has been reported to show variable positivity for lymphatic and vascular endothelial markers: in some cases, only lymphatic dilation is observed, while in others, no markers are expressed.

Two mechanisms have been proposed to explain the blister-like appearance: (a) stenosis or obstruction of lymphatic or blood vessels due to external stimuli or tumor growth, resulting in secondary stasis and edema;² or (b) external forces may damage and dilate lymphatic vessels, allowing lymph fluid to accumulate in the dermis and produce a bullous appearance.² In Case 1, blistering was thought to result from the mechanism described in (b), while in Case 2, it appeared to be caused by the mechanism described in (a).

We conducted a retrospective study of 92 patients, including the two cases presented in this report, who were diagnosed with bullous or anetodermic pilomatricoma (Table 1). Demographic and clinical data, including age, sex, and lesion location, were collected. The mean age of the patients was 21.4 years, with a median of 18 years, the oldest being 70 years,³ and the youngest 5 years. Notably, only one case involved a child under 6 years of age.⁴ No significant sex difference was observed. The most common lesion sites were the upper extremities (42.4%), followed by the trunk (38.0%), with the back (15.2%) and shoulders (14.1%) being particularly affected. No laterality preference was noted. Consistent with previous reports,⁵ the bullous variant of pilomatricoma was less frequently observed on the head and neck, which are common sites for conventional pilomatricoma. Instead, it was more frequently found in regions subjected to mechanical stress, such as the shoulder and back.

While most cases of pilomatricoma with bullous lesions have been documented in teenagers and young adults,⁵ occurrences in young children are rare (cases of 6 years old and under, 3/92: 3.3%).

These rare cases suggest that the pathogenesis of pilomatricoma with bullous lesions may vary depending on the age of onset and individual circumstances.

References

1. Erdoğan HK, Kaya Z, Aytıp ÇD, et al. A rare variant of pilomatricoma: pseudobullous pilomatricoma. *Acta Dermatovenerol Alp Pannonica Adriat* 2015;24:59-60.
2. Fetil E, Soyak MC, Menderes A, et al. Bullous appearance of pilomatricoma. *Dermatol Surg* 2003;29:1066-7.
3. Dev A, Vinay K, Chatterjee D, et al. Anetodermic pilomatricoma: A clinical, histopathological and dermoscopic perspective. *Australas J Dermatol* 2022;63:513-5.
4. Liu J, Liu X, Qu Y, et al. Dermatoscope assisted diagnosis of adolescent bullous pilomatricoma: six case reports. *BMC Pediatr* 2024;24:437.
5. Nam KH, Lee SK, Lee IJ, et al. Clinicopathological and immunohistochemical characteristics of bullous pilomatricoma: a retrospective, single-center study, and comparison with ordinary pilomatricoma. *An Bras Dermatol* 2024;99:362-9.

Figure 1. Clinical and histopathological findings in Case 1 (A-F) and Case 2 (G-I).

A) A 25-mm, mobile, well-defined, firm subcutaneous nodule was located on the left shoulder extending to the upper back. A 20-mm, soft, dome-shaped, erythematous, broad-based pedunculated nodule was situated directly above it. (B, C) The raised erythematous nodular area overlying the pilomatricoma showed a spongy appearance with a densely dilated lumen. (D-F) Endothelial cells within the luminal-like structure were predominantly CD34-positive, with partial D2-40 positivity and scattered CD31 expression. (G, H) A 20-mm, firm, subcutaneous nodule was present on the right upper arm. A 5-mm, soft, dome-shaped, pinkish-red nodule was observed directly above it. (I) Dilated and edematous intradermal lymphatic vessels were observed over the pilomatricoma. Hematoxylin and eosin staining: (B, C, I), CD34: (D), D2-40: (E), CD31: (F). Original magnification: (B) $\times 10$; (C, F, I) $\times 20$, (D, E) $\times 40$.

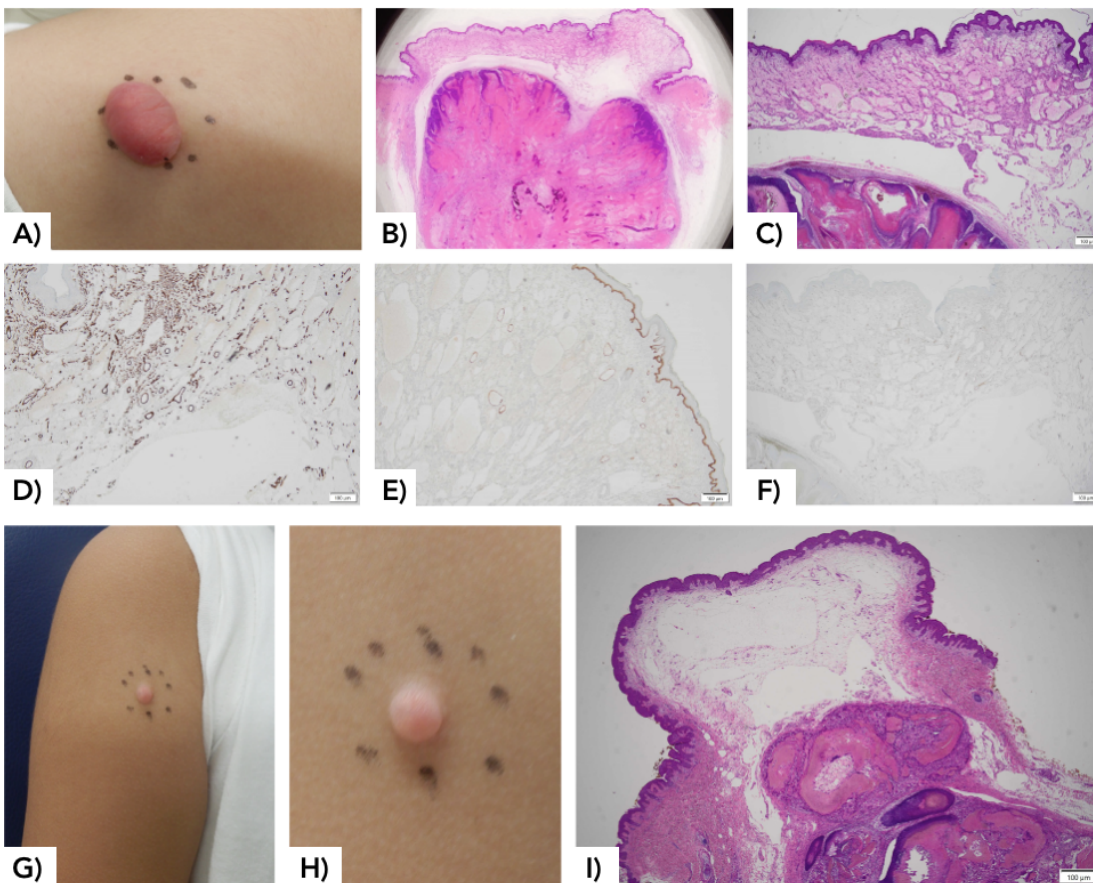


Table 1. Demographic data of patients with bullous pilomatricoma (N=92).

	N (%)
Sex	
Male	47 (51.1)
Female	45 (48.9)
Age (years)	
0-9	9 (11.4)
10-19	37 (46.8)
20-29	20 (25.3)
30-39	6 (7.6)
40-49	3 (3.8)
50-59	1 (1.3)
60-69	2 (2.5)
70-79	1 (1.3)
Location	
Head	4 (4.3)
Face	5 (5.4)
Neck	5 (5.4)
Trunk	35 (38.0)
Back	14 (15.2)
Shoulder	13 (14.1)
Upper extremities	39 (42.4)
Lower extremities	4 (4.3)
Laterality preference	
Shoulder	

Right	6 (54.5)
Left	5 (45.5)
Upper extremities	
Right	14 (48.3)
Left	15 (51.7)
Lower extremities	
Right	1 (50.0)
Left	1 (50.0)