

## Diagnostic challenges and importance of early multidisciplinary intervention in acral melanoma: a case report

Fortunato Cassalia,<sup>1,2</sup> Paolo Del Fiore,<sup>2</sup> Andrea Danese,<sup>3</sup> Michele Soldà,<sup>4</sup> Vincenzo Furfaro,<sup>4</sup> Simone Mocellin<sup>2</sup>

<sup>1</sup>Dermatology Unit, Department of Medicine, University of Padua; <sup>2</sup>Soft-Tissue, Peritoneum and Melanoma Surgical Oncology Unit, Veneto Institute of Oncology IRCCS, Padua; <sup>3</sup>Section of Dermatology and Venereology, Department of Medicine, University of Verona; <sup>4</sup>Operational Unit Orthopaedics and Traumatology, San Lorenzo Hospital, Valdagno, Vicenza, Italy

### Abstract

Acral melanoma (AM) is a rare subtype of melanoma that occurs on acral sites such as the palms, soles, and subungual regions. Due to its atypical presentation and frequent lack of pigmentation in the amelanotic variant (AAM), diagnosis is often delayed, leading to a poor prognosis. We present the case of a 69-year-old woman with a chronic nail lesion that was initially misdiagnosed as onychomycosis and treated with partial onychectomy without histological evaluation. The lesion persisted, and subsequent dermatological evaluation revealed an ulcerated exophytic mass, which was confirmed as an acral nodular melanoma with a Breslow thickness of 7.5 mm. Despite surgical amputation, the patient's management was complicated by wound infection and limited therapeutic options due to comorbidities. This case highlights the diagnostic challenges of AM and emphasizes the importance of early histopathological assessment and multidisciplinary collaboration for timely intervention and improved outcomes.

**Key words:** acral melanoma; amelanotic melanoma; delayed diagnosis; histopathology; multidisciplinary management.

Correspondence: Fortunato Cassalia, Soft-Tissue, Peritoneum and Melanoma Surgical Oncology Unit, IOV – Veneto Institute of Oncology IRCCS, via Gattamelata, 64, 35128 Padua, Italy. E-mail: Fortunato1287@gmail.com

### Introduction

Acral melanoma (AM) is a rare and challenging subtype of melanoma that develops on acral sites, including the palms, soles, and subungual areas.<sup>1</sup> Unlike other melanomas, which are often associated with sun exposure, acral melanomas occur in areas that are typically protected from ultraviolet (UV) radiation. This distinction makes AM unique and complicates its diagnosis and management. It accounts for a small percentage of all melanoma cases but is more common in people with darker skin tones. It is the most common form of melanoma in African, Asian, and Hispanic populations.

The clinical presentation is highly variable, often mimicking benign conditions such as warts, calluses, fungal infections, or subungual hematomas (bruises under the nail). This resemblance to non-malignant lesions often leads to delays in diagnosis, which negatively affects patient outcomes. The amelanotic variant of acral melanoma, acral amelanotic melanoma (AAM), characterized by the absence of typical pigmentation, presents additional diagnostic challenges.<sup>2</sup> These non-pigmented lesions can be easily mistaken for benign conditions, further delaying accurate diagnosis and treatment. Often, these melanomas do not exhibit the classic ABCDE (asymmetry, border irregularity, color variation, diameter, evolution) features, making early clinical assessment difficult.

Histologically, AM, like other melanomas, is characterized by atypical melanocytes. However, diagnosis of these lesions requires a high index of suspicion and often depends on biopsy and

histopathological examination.<sup>3</sup> Immunohistochemical staining for markers such as S100, HMB-45, Melan-A, or PRAME may help to confirm the diagnosis.

Prognostically, AM tends to have a worse outcome than other melanomas, mainly due to delayed diagnosis.<sup>4,5</sup> It often presents at a more advanced stage and has a higher propensity to metastasize.

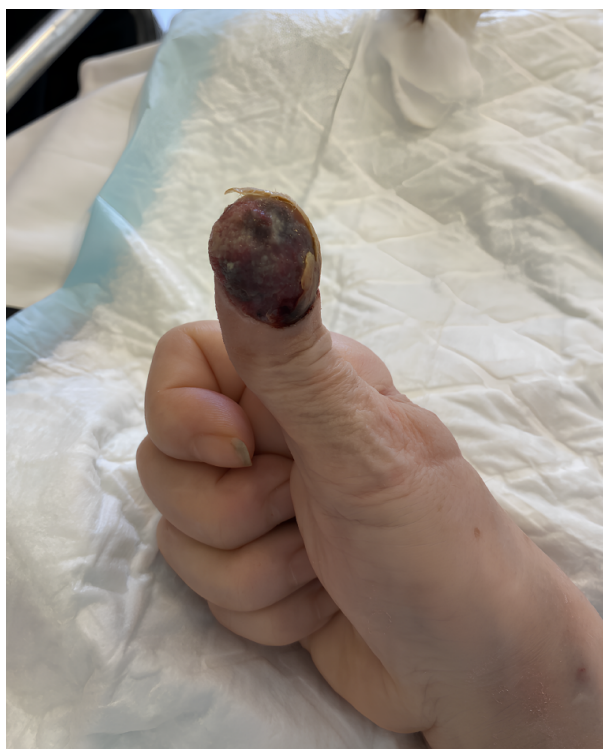
Treatment typically involves surgical excision with appropriate margins and, in advanced cases, may include disarticulation, lymph node dissection, and/or targeted therapy and/or immunotherapy.

Given the diagnostic challenges and aggressive nature of AM, it is critical for clinicians to maintain a high index of suspicion for persistent, non-healing lesions on acral sites. Clinical suspicion, fostered by multidisciplinary teamwork, early biopsy, and histopathological analysis performed in specialized dermatopathology centers, is essential to differentiate these malignancies from benign conditions and to initiate timely and appropriate treatment.<sup>6</sup> We present a clinical case of a 69-year-old female patient with a chronic nail lesion that was subsequently diagnosed as melanoma.

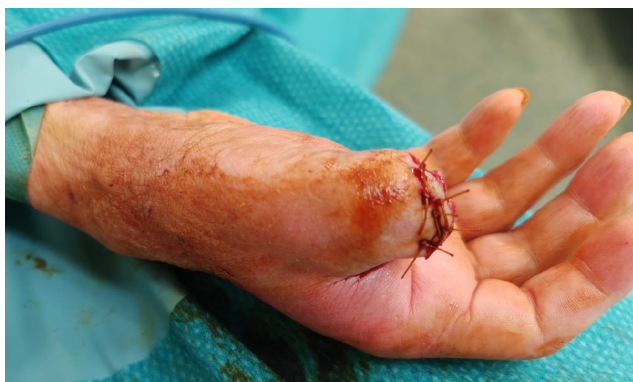### Case Report

A 69-year-old woman was admitted to the orthopedic department for a peritrochanteric fracture. On admission, the orthopedists also noted a nail lesion that had not responded to topical treatment.

The woman reported that this lesion had been present for approximately 2 years and that she had undergone partial onychectomy approximately 8 months previously on suspicion of onychomycosis without histological examination. The patient was then referred for dermatological assessment, which revealed a large ulcerated swelling on the first ray of the right hand (Figure 1), raising the suspicion of a potentially malignant lesion. Consequently, an urgent biopsy was performed, which unfortunately confirmed a diagnosis of melanoma. Histopathological findings revealed an ulcerated acral nodular melanoma with a Breslow thickness of 7.5 mm and a mitotic rate of 8/mm<sup>2</sup>. Pathological staging was pT4bN0M0 (Stage IIC). The patient underwent distal phalangeal amputation<sup>7</sup> with clear surgical margins (Figure 2), but her postop-



**Figure 1.** Clinical presentation on first examination: voluminous ulcerated exophytic neof ormation of the right hand first ray, completely replacing the distal phalanx.



**Figure 2.** Clinical presentation after distal phalangeal amputation.

erative course was complicated by stump infection and wound dehiscence, necessitating further surgical intervention and prolonged antibiotic therapy. The patient had comorbidities, including osteoporosis with vertebral fractures, depressive syndrome, and severe functional decline (Karnofsky score 50; Eastern Cooperative Oncology Group [ECOG] 3), which precluded the use of immunotherapy due to her fragile condition and a body weight of only 39 kg. Currently, the patient is alive, disease-free, and under regular follow-up.

## Discussion and Conclusions

AMs pose significant diagnostic challenges. These melanomas are rare, accounting for a small percentage of all melanomas, and their clinical presentation often mimics benign conditions such as warts, calluses, or infections. This similarity can lead to misdiagnosis and delays in appropriate treatment, with serious consequences for patient outcomes. In this case, the patient's lesion was initially suspected to be infectious, and the lack of histological examination during the initial partial onychectomy contributed to the delay in diagnosis of melanoma. This highlights a critical gap in the diagnostic process for acral lesions and emphasizes the need for early biopsy and histopathological evaluation, especially for lesions that do not respond to standard treatment. Early biopsy and histological analysis are critical in differentiating benign from malignant lesions. In the absence of pigmentation, as seen in amelanotic melanoma, immunohistochemical markers such as PRAME, S100, HMB-45, and Melan-A can aid in the differential diagnosis process. Recently, the underutilization of biopsy for suspicious lesions, particularly in the lower extremities, has been identified as a significant factor contributing to diagnostic delay.<sup>3</sup> Clinicians should maintain a high level of vigilance for non-healing or atypical lesions, particularly in older patients with a history of chronic nail or skin problems. Persistent lesions that do not respond to treatment should prompt consideration of more serious conditions, including melanoma. In this case, the orthopedic team was pivotal in quickly recognizing the complexity of the condition and ensuring timely referral. Recognizing the limitations of standard care and opting for referral to a central cancer referral center demonstrates both sound clinical judgment and a commitment to collaborative practice. The challenges of melanoma, particularly atypical presentations, emphasize the need for seamless communication between local providers and central expertise. A well-integrated professional network ensures that patients benefit from a broad range of expertise. By bringing together dermatologists, oncologists, surgeons, and pathologists, healthcare teams can deliver exceptional outcomes in even the most complex settings, highlighting the key value of multidisciplinary collaboration.<sup>8,9</sup>

## References

1. Darmawan CC, Jo G, Montenegro SE, et al. Early detection of acral melanoma: a review of clinical, dermoscopic, histopathologic, and molecular characteristics. *J Am Acad Dermatol* 2019;81:805-12.
2. Gong HZ, Zheng HY, Li J. Amelanotic melanoma. *Melanoma Res* 2019;29:221-30.
3. Cassalia F, Danese A, Cocchi E, et al. Misdiagnosis and clinical insights into acral amelanotic melanoma: a systematic review. *J Pers Med* 2024;14:518.

- Lezcano C, Jungbluth AA, Nehal KS, et al. PRAME expression in melanocytic tumors. *Am J Surg Pathol* 2018;42:1456-65.
- Cassalia F, Danese A, Tudurachi I, et al. PRAME updated: diagnostic, prognostic, and therapeutic role in skin cancer. *Int J Mol Sci* 2024;25:1582.
- Stagner AM, Tahan SR, Nazarian RM. Changing trends in dermatopathology case complexity: a 9-year academic center experience. *Arch Pathol Lab Med* 2021;145:1144-7.
- Guarneri C, Bevelacqua V, Semkova K, et al. Subungual acrolentiginous amelanotic melanoma treated with amputation of the distal and middle phalanges. *Wien Med Wochenschr* 2013;163:368-71.
- Perez M, Abisaad JA, Rojas KD, et al. Skin cancer: primary, secondary, and tertiary prevention. Part I. *J Am Acad Dermatol* 2022;87:255-68.
- Rojas KD, Perez ME, Marchetti MA, et al. Skin cancer: primary, secondary, and tertiary prevention. Part II. *J Am Acad Dermatol* 2022;87:271-88.

---

Received: 11 March 2024; Accepted: 26 April 2025.

Conflict of interest: the authors declare no potential conflict of interest.

Ethics approval and consent to participate: no ethical committee approval was required for this case report by the Department because this article does not contain any studies with human participants or animals. Informed consent was obtained from the patient included in this study.

Consent for publication: the patient gave her written consent to use her personal data for the publication of this case report and any accompanying images.

Availability of data and materials: all data underlying the findings are fully available.

*Publisher's note: all claims expressed in this article are solely those of the authors and do not necessarily represent those of their affiliated organizations, or those of the publisher, the editors and the reviewers. Any product that may be evaluated in this article or claim that may be made by its manufacturer is not guaranteed or endorsed by the publisher.*

*This work is licensed under a Creative Commons Attribution-NonCommercial 4.0 International License (CC BY-NC 4.0).*