

Efficacy of a topical polyphenol-based formulation in palmoplantar psoriasis: an observational study

Simone Amato,¹ Annunziata Dattola,¹ Luigi Bennardo,² Martina Tolone,¹ Steven Paul Nisticò¹

¹Dermatology Unit, Department of Clinical Internal Anesthesiologic Cardiovascular Sciences, Sapienza University of Rome;

²Science of Health Department, School of Medicine, University Magna Graecia, Catanzaro, Italy

Abstract

This single-arm observational study evaluated the efficacy and safety of a novel topical formulation containing a complex mixture of polyphenols (CMP) – a proprietary blend rich in oleocanthal and oleuropein aglycone (each >60%), along with hydroxytyrosol and other extra virgin olive oil (EVOO)-derived polyphenols – combined with triticum vulgare germ (TVG) oil, betaine, propanediol, and tocopheryl acetate in patients with mild palmoplantar psoriasis (PPP). Twenty participants (aged 20-55) applied the formulation twice daily for 8 days, with assessments conducted on days 0 (baseline), 5, and 8. Participants underwent a 60-day follow-up to assess the durability of benefits and potential late-onset adverse events. Clinical evaluations measured lesion extent, keratinization, inflammation, desquamation, and infiltration. A patient-reported questionnaire evaluated quality of life (QoL) and symptom burden. By day 8, the mean lesion extent had decreased by approximately 40%, inflammation had improved by about 50%, and desquamation had resolved fully in most cases. Patient-reported outcomes improved alongside clinical measures. At day 60, these improvements persisted in 85% of participants, and no adverse events emerged. The formulation's mechanism of action is hypothesized to involve the concerted antioxidant and anti-inflammatory activities of polyphenols (oleocanthal, oleuropein aglycone, and hydroxytyrosol) in synergy with TVG oil's supportive lipid matrix and other excipients. These findings suggest that EVOO-derived polyphenols formulated in TVG oil may serve as a valuable adjunct for managing PPP with good tolerability and sustained benefits.

Key words: palmoplantar psoriasis; oleocanthal; oleuropein aglycone; hydroxytyrosol; triticum vulgare germ oil.

Correspondence: Simone Amato, Dermatology Unit, Department of Clinical Internal Anesthesiologic Cardiovascular Sciences, Sapienza University of Rome, 00185 Rome, Italy. E-mail: simonamato94@gmail.com. Tel.: +39 339.3977680.

Introduction

Palmoplantar psoriasis (PPP) is a localized variant of psoriasis that affects the palms and soles, presenting as erythematous, scaly plaques. It compromises daily functioning, affecting approximately 3-4% of psoriasis patients and significantly impacting their quality of life (QoL).¹⁻³ The pathophysiology of PPP involves dysregulated immune responses, particularly characterized by the activation of T-helper 17 (Th17) cells that produce proinflammatory cytokines, notably interleukin-17 (IL-17) and IL-23, playing critical roles in sustaining the inflammatory cycle and epidermal hyperproliferation associated with psoriasis.^{4,5} The immune-mediated response observed in PPP underscores the necessity for targeted and effective therapeutic approaches. Conventional therapies for PPP, such as topical corticosteroids, vitamin D analogs, and systemic agents, often provide inconsistent results and may carry substantial side effects.^{2,3,5,6} As such, there is rising interest in alternative topical treatments, particularly those utilizing natural compounds like polyphenols. Extra virgin olive oil (EVOO) is rich in polyphenolic compounds such as oleocanthal, known for its anti-inflammatory and antioxidant properties.⁷ Research indicates that oleocanthal can inhibit cyclooxygenase (COX) enzymes, reducing proinflammatory mediators, thereby mitigating inflammatory responses.⁸⁻¹⁰

Additionally, other compounds from EVOO, like oleuropein aglycone and hydroxytyrosol, exhibit properties that may ameliorate the inflammatory processes characteristic of psoriasis by modulating essential signaling pathways.^{8,11} To enhance the localization and effectiveness of these polyphenols, recent studies have explored innovative formulation methods that utilize specialized lipid carriers. One example is triticum vulgare germ (TVG) oil, which consists of several beneficial ingredients that not only nourish the skin but also enhance the delivery of active compounds. These ingredients include unsaturated fatty acids, tocopherols, and phytosterols, which support skin hydration and barrier functions.^{5,12} The incorporation of solubilizing excipients, such as betaine and propanediol, further stabilizes these formulations, thereby improving their therapeutic efficacy.^{13,14} In light of the aforementioned points, a single-arm observational study was conducted to evaluate a topical formulation based on a complex mixture of polyphenols (CMP), a blend rich in oleocanthal and oleuropein aglycone (each >60%), along with hydroxytyrosol, combined with TVG oil and supportive excipients. Clinical outcomes were assessed over both short (8 days) and long (60 days) durations, measuring various parameters such as lesion extent, keratinization, and inflammation, along with patient-reported outcomes concerning treatment tolerability and QoL.^{5,15-17} This study aims to investigate whether a formulation enriched with

EVOO-derived polyphenols can serve as a viable alternative for patients with mild PPP, potentially addressing the limitations of current conventional treatments.

Materials and Methods

Study design

A prospective, single-arm, open-label clinical observational study was conducted to evaluate changes in skin parameters over 8 days in participants with mild PPP. An extended follow-up at day 60 assessed the persistence of beneficial effects and any delayed adverse events. The study was conducted at the Dermatology Unit of Sapienza University of Rome and the Dermatology Unit of the University of Catanzaro (Italy). The local Institutional Review Board approved the study, and informed consent was obtained from all participants.

Participants

Twenty participants (10 male, 10 female), aged 20-55, with clinically confirmed mild PPP, were enrolled. Inclusion criteria comprised: i) palmoplantar plaque extent of 50-80% in the affected area; ii) moderate to severe inflammation as assessed by a standardized severity scale; and iii) no systemic psoriasis therapies in the preceding 30 days. Exclusion criteria included: i) generalized psoriasis; ii) recent topical corticosteroid use (<30 days); and iii) comorbid dermatologic or systemic diseases interfering with study outcomes.

Intervention

The formulation used in this study contained: i) CMP, a proprietary blend rich in oleocanthal and oleuropein aglycone (each >60%), along with hydroxytyrosol and other polyphenols extracted from EVOO; ii) TVG oil, a carrier base delivering unsaturated fatty acids, phytosterols, vitamins (E, B-complex), and squalene; iii) propanediol, a solubilizing agent that enhances penetration and ensures cosmetic acceptability; iv) betaine, an osmoprotectant that supports skin hydration; and v) tocopheryl acetate, an antioxidant and membrane stabilizer. Participants applied the product twice daily (morning and evening) for 8 consecutive days. Follow-up visits occurred on days 5 and 8. A final follow-up on day 60 confirmed the durability of clinical responses and the absence of late-onset adverse effects.

Patient-reported outcomes

Investigators employed a brief, validated questionnaire to capture patient-reported outcomes (PRO). This questionnaire included items on: i) lesion-related discomfort (pain, pruritus); ii) perceived functional limitations (manual tasks, ambulation); iii) general QoL domains (daily activities, social participation); iv) overall treatment satisfaction. Each domain was graded on a 5-point Likert scale (0 = no impact, 4 = severe impact). Scores were collected at baseline, day 8, and day 60.

Clinical assessments

The primary outcomes involved changes in lesion extent (% involvement), keratinization (grade 1-4), inflammation (mild, moderate, severe), desquamation (mild, moderate, severe, absent), and infiltration (mild, moderate, severe). In this study, keratinization was assessed based on the observed thickness and induration of the psoriatic plaques (graded 1-4, where 1 indicated “absent” and 4 “severe thickening”). Desquamation was evaluated separately based on the extent and character of visible scaling and peeling of the stratum corneum (categorized as absent, mild, moderate, or severe). While related, these parameters were considered distinct to provide a comprehensive assessment of epidermal changes. This distinction is particularly pertinent in the context of PPP, which often presents with notable hyperkeratosis (thickening); evaluating this aspect separately from the process of scale shedding (desquamation) allows for a more nuanced understanding of this specific disease manifestation and its response to treatment. Two independent dermatologists conducted assessments using standardized scoring methods and resolved any discrepancies by consensus.

Statistical analysis

Paired *t*-tests compared changes from baseline to day 5, day 5 to day 8, and baseline to day 8. Nonparametric tests were applied to ordinal PRO data (Wilcoxon signed-rank test). Analyses were performed with IBM SPSS Statistics, version 28.0 (IBM Corp., Armonk, NY, USA).

Results

At baseline (day 0), participants exhibited a mean lesion extent of 65% ($\pm 10\%$), with severe keratinization (grade 3-4) and moderate to severe inflammation predominating in 80% of cases (Table 1). Additionally, desquamation and infiltration were pronounced, with

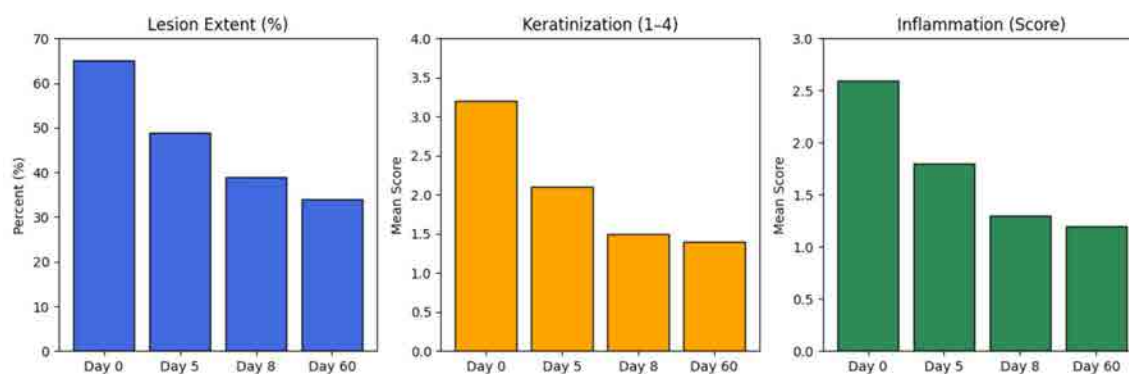


Figure 1. Bar chart comparing lesion extent, keratinization, and inflammation at baseline, day 5, 8, and 60.

Table 1. Clinical data of participants (n=20) at four timepoints.

Participant	Lesion extent (Day 0)	Keratization (Day 0)	Inflammation (Day 0)	Desquamation (Day 0)	Infiltration (Day 0)	Lesion extent (Day 5)	Keratization (Day 5)	Inflammation (Day 5)	Desquamation (Day 5)	Infiltration (Day 5)	Lesion extent (Day 8)	Keratization (Day 8)	Inflammation (Day 8)	Desquamation (Day 8)	Infiltration (Day 8)	Lesion extent (Day 60)	Keratization (Day 60)	Inflammation (Day 60)	Desquamation (Day 60)	Infiltration (Day 60)
1	80%	4 (severe)	Severe	Severe	Severe	60%	3 (moderate)	Mild	Severe	Moderate	50%	2 (mild)	Mild	Moderate	Mild	45%	2 (mild)	Mild	Mild	Mild
2	80%	4 (severe)	Moderate	Severe	Severe	50%	3 (moderate)	Mild	Mild	Moderate	40%	2 (mild)	Severe	Absent	Absent	35%	1 (mild)	Absent	Absent	Mild
3	50%	3 (moderate)	Moderate	Moderate	Moderate	40%	2 (mild)	Mild	Mild	Absent	20%	1 (absent)	Absent	Absent	Absent	15%	1 (absent)	Absent	Absent	Absent
4	60%	2 (moderate)	Moderate	Moderate	Mild	30%	1 (mild)	Mild	Absent	Absent	10%	1 (mild)	Absent	Absent	Absent	10%	1 (mild)	Absent	Absent	Absent
5	70%	4 (severe)	Moderate	Moderate	Mild	60%	3 (moderate)	Mild	Mild	Mild	50%	2 (mild)	Absent	Absent	Absent	40%	2 (mild)	Absent	Absent	Absent
6	50%	2 (moderate)	Moderate	Moderate	Mild	40%	1 (mild)	Mild	Moderate	Moderate	20%	1 (mild)	Absent	Absent	Absent	15%	1 (mild)	Absent	Mild	Mild
7	80%	4 (severe)	Severe	Moderate	Severe	60%	3 (moderate)	Moderate	Moderate	Moderate	50%	1 (mild)	Mild	Mild	Mild	40%	1 (mild)	Mild	Mild	Mild
8	60%	3 (moderate)	Moderate	Moderate	Moderate	50%	2 (mild)	Mild	Moderate	Mild	40%	2 (mild)	Absent	Mild	Mild	35%	1 (mild)	Absent	Mild	Mild
9	70%	4 (severe)	Moderate	Moderate	Moderate	50%	3 (moderate)	Mild	Mild	Mild	40%	2 (mild)	Absent	Absent	Absent	35%	2 (mild)	Absent	Absent	Absent
10	80%	4 (severe)	Severe	Severe	Moderate	50%	3 (moderate)	Moderate	Moderate	Mild	30%	2 (mild)	Mild	Mild	Mild	25%	1 (absent)	Absent	Absent	Absent
11	50%	2 (moderate)	Mild	Mild	Mild	40%	1 (mild)	Absent	Mild	Absent	30%	1 (mild)	Absent	Absent	Absent	25%	1 (mild)	Absent	Absent	Absent
12	60%	3 (moderate)	Moderate	Mild	Mild	50%	2 (mild)	Mild	Mild	Mild	40%	1 (mild)	Absent	Absent	Absent	35%	1 (mild)	Absent	Absent	Absent
13	80%	4 (severe)	Severe	Moderate	Severe	60%	3 (moderate)	Moderate	Moderate	Moderate	50%	2 (mild)	Mild	Mild	Mild	40%	2 (mild)	Mild	Mild	Mild
14	60%	3 (moderate)	Moderate	Moderate	Mild	50%	2 (mild)	Mild	Mild	Mild	40%	1 (mild)	Absent	Mild	Mild	35%	1 (mild)	Absent	Mild	Mild
15	70%	4 (severe)	Moderate	Moderate	Moderate	60%	3 (moderate)	Mild	Mild	Mild	50%	2 (mild)	Absent	Mild	Mild	45%	2 (mild)	Absent	Mild	Mild
16	70%	4 (severe)	Moderate	Moderate	Mild	60%	3 (moderate)	Mild	Mild	Absent	50%	2 (mild)	Absent	Absent	Absent	40%	2 (mild)	Absent	Absent	Absent
17	70%	4 (severe)	Severe	Severe	Moderate	50%	3 (moderate)	Moderate	Moderate	Moderate	40%	2 (mild)	Mild	Mild	Mild	35%	2 (mild)	Mild	Mild	Mild
18	80%	4 (severe)	Moderate	Severe	Moderate	60%	3 (moderate)	Mild	Moderate	Mild	50%	2 (mild)	Absent	Mild	Mild	45%	2 (mild)	Absent	Mild	Mild
19	50%	2 (moderate)	Mild	Mild	Mild	40%	1 (mild)	Absent	Mild	Absent	30%	1 (mild)	Absent	Absent	Absent	25%	1 (mild)	Absent	Absent	Absent
20	60%	3 (moderate)	Moderate	Mild	Mild	50%	2 (mild)	Mild	Mild	Mild	40%	1 (mild)	Absent	Mild	Mild	35%	1 (mild)	Absent	Mild	Mild

Legend for keratinization: 1 = absent, 2 = mild, 3 = moderate, 4 = severe (“absent”, “mild”, “moderate”, and “severe” are provided for clarity alongside numerical grades).

approximately 70% of participants reporting severe desquamation and 60% exhibiting severe infiltration. By day 5, a notable improvement was observed, as lesion extent reduced by approximately 20%, reaching a mean of 50% ($\pm 10\%$). Keratinization scores improved by an average grade of 1 ($p < 0.05$), while inflammation declined by approximately 30%, shifting from moderate to severe levels toward mild to moderate ($p < 0.01$). Desquamation resolved completely in 25% of participants and improved significantly in an additional 40%. Infiltration, initially severe in most cases, was largely reduced to a moderate level (Table 1). At day 8, the improvements became more pronounced, with a decrease in lesion extent of $\sim 40\%$ relative to baseline ($p < 0.01$). Inflammation improved by approximately 50%, with severe cases completely absent. Desquamation resolved in 60% of participants, while in the remaining, it persisted only at a mild level. Infiltration was absent or mild in 80% of cases, indicating a substantial resolution of the condition. Importantly, no immediate adverse events emerged during this period (Tables 1 and 2). These trends are clearly illustrated in Figure 1 (bar chart), which highlights the progressive reduction in lesion extent, keratinization, and inflammation from day 0 to day 60. The 60-day follow-up confirmed that these clinical gains were not only sustained but also showed slight additional improvements in some cases. Lesion extent remained stable or improved slightly (by approximately 5-10%) in 85% of participants compared to day 8. Importantly, no relapse to baseline severity was observed across the cohort, and no late-onset adverse events were reported (Table 1). At baseline, patient-reported outcomes revealed moderate impairment in daily activities (mean Likert score of 2.8 ± 0.6) and frequent pain or discomfort (3.0 ± 0.7). By day 8, a substantial improvement was noted, with a mean decrease of 1.3 ± 0.5 points in overall symptom burden ($p < 0.05$), a reduction in functional limitation scores by 1.0 ± 0.4 points ($p < 0.05$), and an overall QoL enhancement, reflected by a 1.2 ± 0.5 point increase on the 5-point scale ($p < 0.05$) (Table 3). By day 60, these improvements persisted or slightly increased, with most participants reporting sustained symptom relief and high satisfaction levels (mean treatment satisfaction: 4.2 ± 0.5 on a 5-point scale) (Table 3). The PRO scores chart (Figure 2) illustrates these trends, demonstrating

a steady decrease in symptom burden and functional limitations over time, reinforcing the stability of treatment benefits beyond day 8.

Additionally, Figures 3-6 visually underscore the progressive improvements in lesion extent, inflammation, and keratinization during the treatment period, with resolution and maintenance of benefits by day 60. These clinical improvements are evident in Figure 3, which depicts the reduction of palmoplantar lesions, and Figure 4, which highlights the disappearance of scaling and cracking, resulting in smoother and more hydrated skin. Figure 5 presents images of the soles of the feet, demonstrating substantial improvement in desquamation and inflammation. Lastly, Figure 6 illustrates the complete disappearance of fissures and restoration of skin integrity at day 60. Statistical analysis and interpretation revealed significant improvements from day 0 to day 5 and from day 5 to day 8 across all clinical parameters ($p < 0.05$). Between day 8 and day 60, most values remained stable or showed slight enhancement, with $p > 0.05$ in some cases, suggesting a mainte-

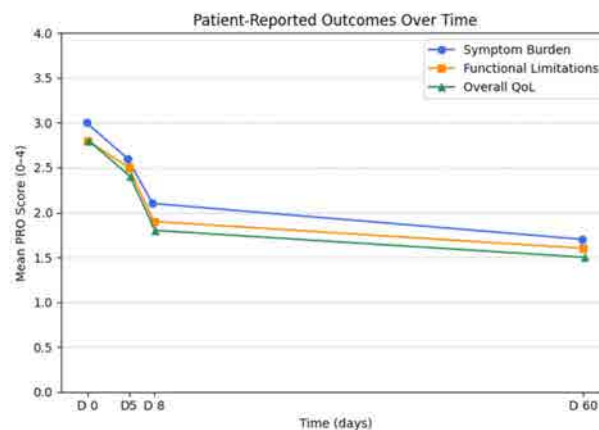


Figure 2. Patient-reported outcomes over time.

Table 2. Summary of clinical parameters (mean values and p-values).

Parameter	Day 0	Day 5	Day 8	Day 60	p (0→5)	p (5→8)	p (8→60)	p (0→60)
Lesion extent (%)	65±10	50±10	40±9	35±8	<0.01	<0.01	0.03	<0.01
Keratinization (1-4)	3.2±0.8	2.1±0.7	1.5±0.5	1.4±0.5	<0.01	<0.01	0.13	<0.01
Inflammation (3-class)	2.6±0.5 (mod-severe)	1.8±0.4 (mild-mod)	1.3±0.4 (mild)	1.2±0.4 (mild)	0.01	<0.01	0.15	<0.01
Desquamation (4-class)	2.7±0.6 (severe-mod)	1.9±0.5 (mild-mod)	1.1±0.4 (mild-absent)	1.0±0.3 (mild-absent)	<0.01	<0.01	0.12	<0.01
Infiltration (3-class)	2.4±0.6 (mod-severe)	1.8±0.4 (mild-mod)	1.2±0.4 (mild-absent)	1.1±0.4 (mild-absent)	0.02	<0.01	0.20	<0.01

Table 3. Patient-reported outcomes: quality of life and symptoms.

Domain	Likert scale	Day 0	Day 8	Day 60	p (0→8)	p (8→60)
Pain/itch	0-4	3.0±0.7	1.8±0.6	1.6±0.5	<0.01	0.20
Functional limitations	0-4	2.8±0.6	1.8±0.4	1.6±0.4	<0.01	0.10
Impact on daily activities	0-4	2.5±0.5	1.3±0.4	1.2±0.4	<0.01	0.16
Treatment satisfaction	0-4 4 (maximum satisfaction)	n.a.	3.5±0.5	4.2±0.5	n.a.	0.02
Overall quality of life	0-4	2.8±0.6	1.6±0.5	1.4±0.5	<0.01	0.15

n.a., not assessed; 0 = no impact; 4 = severe impact.

nance effect rather than further drastic improvement. However, when comparing day 0 to day 60, all parameters demonstrated high statistical significance ($p < 0.01$), confirming the durable and long-term efficacy of the intervention (Table 2). Overall, these findings indicate that the tested polyphenol-based formulation effectively reduces lesion extent, inflammation, desquamation, and infiltration within 8 days, with continued stability and patient-reported improvements sustained over 60 days. The absence of adverse events further highlights the formulation's safety profile, positioning it as a promising therapeutic option for mild PPP.

Discussion

The results of this observational study highlight the considerable potential of a TVG oil-based formulation enriched with EVOO-derived polyphenols – including oleocanthal, oleuropein aglycone, and hydroxytyrosol – in effectively reducing the severity of psoriatic plaques in the palmoplantar regions. Throughout the 8-

day treatment, participants exhibited a notable decrease in lesion extent by approximately 40% and an impressive improvement in inflammation, approximately 50%. The resolution of desquamation and infiltration in a significant proportion of participants further attests to the formulation's efficacy. Notably, the 60-day follow-up indicated that these clinical gains not only persisted but also occurred without any delayed adverse effects, suggesting a robust safety profile for the treatment. These findings align with existing literature that describes the anti-inflammatory capabilities of oleocanthal, particularly its inhibition of COX enzymes, alongside the antioxidant and anti-inflammatory activities attributed to oleuropein aglycone and hydroxytyrosol.¹³⁻¹⁵ However, further studies are needed to confirm direct penetration and biological activity within psoriatic lesions. The therapeutic impact of these compounds through topical application is noteworthy, as studies have demonstrated that phenolic compounds can modulate important cytokine expressions such as tumor necrosis factor (TNF)- α , IL-1 β , and IL-6, as well as influence transcription factors like nuclear factor kappa-light-chain-enhancer of activated B cells

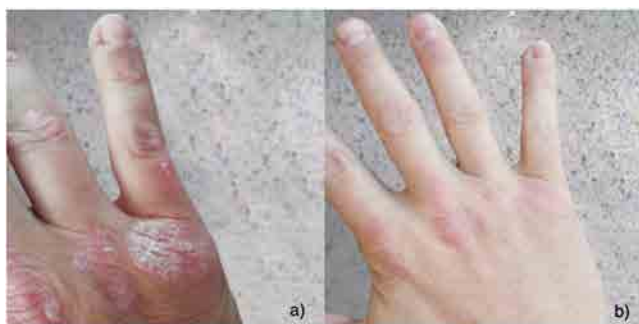

Figure 3. Images showing the dorsum of the right hand at day 0 (a) and day 8 (b) reveal a clear reduction in lesion size and inflammation, with marked improvement in skin texture. At day 0, erythema and scaling are evident, while by day 8, there is a significant decrease in redness and scaling.

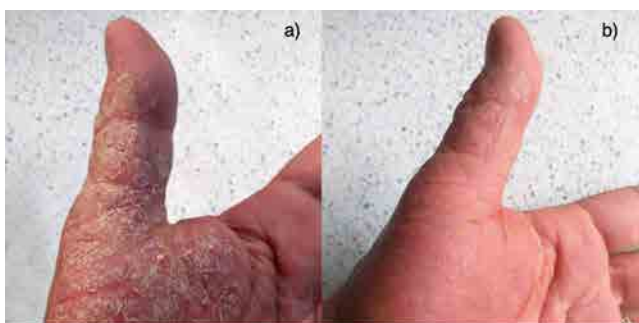

Figure 4. Images of the palm of the left hand, specifically the thenar eminence, demonstrate the effects of the treatment on days 0 and 8. On day 0 (a), the lesion is prominent, with moderate inflammation and desquamation. By day 8 (b), the lesion has almost completely resolved, with a noticeable reduction in both inflammation and scaling.

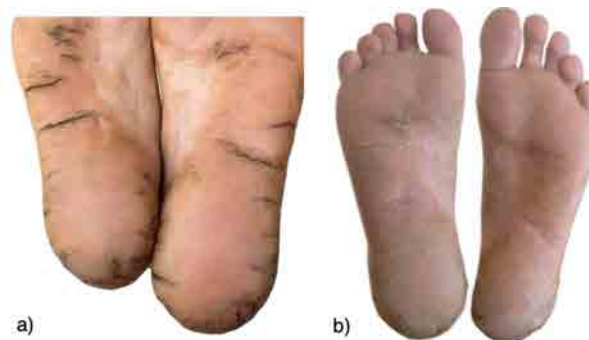

Figure 5. Images of the soles of the feet, taken at day 0 (a) and day 8 (b), show a reduction in the extent of lesions. On day 0, severe desquamation and moderate inflammation are observed. By day 8, both desquamation and inflammation are substantially reduced, and the skin appears smoother and more hydrated.

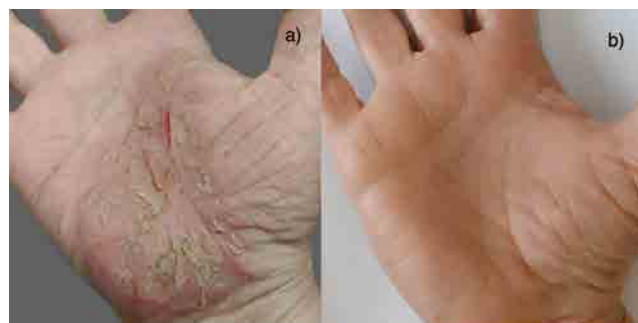

Figure 6. Palm images at day 0 (a) and day 60 (b) document a complete reduction in flaking and cracking, along with improved skin texture and hydration. On day 0, peeling and cracking are clearly visible in the central region of the palm. At day 60, the lesions have disappeared, and the skin surface appears smooth, reflecting a notable improvement in the severity of palmoplantar lesions during this interval.

(NF- κ B), a critical pathway involved in psoriatic pathology.^{16,17} The formulation's incorporation of TVG oil, rich in essential lipids and vitamins, likely provided significant fortification to the skin barrier in these thickly keratinized areas, thereby enhancing the penetration and local bioavailability of the polyphenols.^{18,19} This interplay among polyphenols, TVG oil, and excipients (propanediol, betaine, and tocopheryl acetate) presumably elucidates the robust improvements observed within the relatively short treatment period of 8 days. Patient-reported outcomes further supported the clinical evaluations, demonstrating a significant reduction in symptom burden, enhancement of functional capacity, and overall improvements in QoL. Given that PPP can result in greater functional impairment compared to plaque psoriasis impacting other body areas,^{3,4} the resulting improvements are particularly salient. This enhancement in daily functioning, particularly for participants whose professions require frequent hand use or prolonged periods of standing, underscores the real-world applicability and clinical relevance of this formulation. While the observational nature of the study presents an opportunity to derive clinical insights, it is crucial to recognize the positive implications of these findings as a foundation for future research.¹⁹⁻²² The encouraging outcomes exhibited within this cohort set a precedent, advocating for further exploration into the comprehensive therapeutic potential of EVOO-derived polyphenols combined with specialized lipid carriers. Large-scale, randomized, placebo-controlled trials with extended follow-up will be essential for affirming not only the efficacy and safety profile of this innovative formulation but also its potential to influence standard treatment paradigms for patients with PPP. In conclusion, the positive results from this observational study provide compelling evidence that a TVG oil-based formulation containing EVOO-derived polyphenols represents a promising addition to the therapeutic arsenal for managing PPP. The observed clinical benefits suggest this formulation may be a promising adjunct treatment, warranting further controlled trials.

These findings suggest that clinicians could integrate a TVG oil-based polyphenolic formulation into existing management paradigms for PPP to reduce the inflammatory burden while maintaining skin barrier integrity. This adjunct approach may be especially valuable for individuals with mild disease who prefer non-steroidal options or for those who require a maintenance product that carries a minimal risk of adverse events. The favorable safety profile and sustained efficacy at day 60 hint at the product's viability as a longer-term management strategy.

Conclusions

This observational study demonstrated that an innovative topical formulation containing oleocanthal, oleuropein aglycone, hydroxytyrosol, and TVG oil exerts significant anti-inflammatory and lesion-reducing effects in patients with mild PPP. The 8-day intervention yielded clinically and statistically significant improvements across multiple parameters, and these benefits remained stable at day 60, with no adverse events. Mechanistic considerations support the notion that polyphenols, when delivered through a robust lipid matrix (TVG oil) and combined with additional excipients, can penetrate thick psoriatic lesions and mitigate keratinocyte hyperproliferation and local inflammation. The integration of patient-reported outcomes confirmed improvements in QoL and symptom control. While the findings suggest that the CMP-based formulation is well-tolerated and may provide clinical benefits, the observational nature of the study and the absence of a

comparator group necessitate cautious interpretation. Future controlled trials are essential to confirm efficacy.

References

1. Chung JH, Rich P, Lee JH, et al. Palmoplantar psoriasis is associated with greater impairment of health-related quality of life compared with moderate to severe plaque psoriasis. *J Am Acad Dermatol* 2014;70:698-703.
2. Colao JM, Mrowietz U, Augustin M, Reich K. Successful treatment of palmoplantar psoriasis using combination acitretin and apremilast: A case report. *J Psoriasis Psoriatic Arthritis* 2016;1:85-288.
3. Muqrin N, AlGhamdi K, AlTarakji R, AlQahtani M. Rapid response of palmoplantar psoriasis to risankizumab: A case report. *Clin Cosmet Investig Dermatol* 2022;15:897-901.
4. Wang CQ, Haxhinasto S, Garcet S, et al. Comparison of the inflammatory circuits in psoriasis vulgaris, non-pustular palmoplantar psoriasis, and palmoplantar pustular psoriasis. *J Invest Dermatol* 2023;143:87-97.e14.
5. Engin B, Aşkın Ö, Tüzün Y. Palmoplantar psoriasis. *Clin Dermatol* 2017;35:19-27.
6. Darakjian LI, Rigakou A, Brannen A, et al. Spontaneous In Vitro and In Vivo Interaction of (-)-Oleocanthal with Glycine in Biological Fluids: Novel Pharmacokinetic Markers. *ACS Pharmacol Transl Sci* 2021;4:179-92.
7. Nisticò SP, Greco ME, Amato S, et al. Evaluating the impact of oleocanthal and oleacein on skin aging: results of a randomized clinical study. *Medicina (Kaunas)* 2024;60.
8. Akl M, Ayoub NM, Mohyeldin MM, et al. Olive phenolics as c-Met inhibitors: (-)-oleocanthal attenuates cell proliferation, invasiveness, and tumor growth in breast cancer models. *PLoS One* 2014;9:e97622.
9. Pei J, He Y, He T, et al. (-)-Oleocanthal inhibits growth and metastasis by blocking activation of STAT3 in human hepatocellular carcinoma. *Oncotarget* 2016;7:70669-82.
10. Batarseh A, Kaddoumi A. Oleocanthal-rich extra-virgin olive oil enhances donepezil effect by reducing amyloid- β load and related toxicity in a mouse model of Alzheimer's disease. *J Nutr Biochem* 2018;62:76-85.
11. Ayoub N, Mohyeldin MM, Ebrahim HY, et al. The olive oil phenolic (-)-oleocanthal modulates estrogen receptor expression in luminal breast cancer in vitro and in vivo and synergizes with tamoxifen treatment. *Eur J Pharmacol* 2017;795:16-27.
12. Montoya M, García JJ, Salazar R, et al. Oleocanthal modulates LPS-induced murine peritoneal macrophages activation via regulation of inflammasome, Nrf-2/HO-1, and MAPKs signaling pathways. *J Agric Food Chem* 2019;67:2920-9.
13. Ruiz-García J, González-Domínguez R, Pascual-Vaca Á, et al. Rich oleocanthal and oleacein extra virgin olive oil and inflammatory and antioxidant status in people with obesity and pre-diabetes. The APRIL Study: a randomised, controlled crossover study. *Preprints* 2023.
14. Iacono F, Ferrara L, Ferraraccio F, et al. Effect of oleocanthal and its derivatives on inflammatory response induced by lipopolysaccharide in a murine chondrocyte cell line. *Arthritis Rheumatol* 2010;62:3824-32.
15. Duffin K, Yeung H, Takeshita J, et al. Characterization of patients with psoriasis in challenging-to-treat body areas in the Corrona Psoriasis Registry. *Dermatology* 2020;236:485-90.

16. Rompoti N, Koutouzi K, Menexes G. Phenolic compounds: a new generation of anti-inflammatory agents. *Antioxidants (Basel)* 2019;8:211.
17. Chung KT, Wong TY, Wei CI, et al. Tannins and their biochemical properties. *Crit Rev Food Sci Nutr* 2014;54:153-71.
18. Muqrin AS, Shaikh AA, Zareef M. Formulation and evaluation of topical applications of herbal oil emulsion containing natural phenolic compounds. *Cosmetics* 2022;9:85.
19. Alajlan MM, Qadoumi MH. The role of lipid-based nanoformulations in the delivery of polyphenols. *Int J Nanomedicine* 2021;16:8659-82.
20. Zhang X, Zhang M, Zhu Q, et al. Oleocanthal and other phenolic compounds from olive oil modulate the inflammatory response in human monocytes. *J Funct Foods* 2019;58:117-28.
21. Moussa AWS, Nasr AM, Elkabarity RH, Khalil MF. The synergistic effect of olive leaf extract and vitamin E in healing cutaneous wounds: a randomized clinical trial. *J Dermatol Treat* 2020;31:634-41.
22. Watts MF, Martin KS, Brown BJ, et al. Dietary polyphenols and their role in modulating inflammatory pathways in chronic disease. *Eur J Nutr* 2017;57:147-58.

Received: 10 March 2025; Accepted: 8 June 2025.

Contributions: Simone Amato: conceptualization, data analysis and interpretation, writing – original draft, statistical analyses, writing – review & editing; Steven Paul Nisticò: conceptualization; Annunziata Dattola, Martina Tolone: statistical analyses, writing – review & editing; Luigi Bennardo: data interpretation, revision. All authors read and approved the final version of the manuscript and agreed to be accountable for all aspects of the work.

Conflict of interest: the authors have no conflict of interest to declare.

Ethics approval and consent to participate: the study was conducted according to the Declaration of Helsinki (2013) and approved by the Institutional Review Board of the Dermatology Unit of Sapienza University of Rome and the Dermatology Unit of the University of Catanzaro (Protocol n. 374, 17 December 2019). Written informed consent was obtained from all participants.

Consent for publication: patients gave their written consent to use their personal data for the publication of this study and any accompanying images.

Availability of data and materials: the data used to support the findings of this study are available from the corresponding author upon reasonable request.

Publisher's note: all claims expressed in this article are solely those of the authors and do not necessarily represent those of their affiliated organizations, or those of the publisher, the editors and the reviewers. Any product that may be evaluated in this article or claim that may be made by its manufacturer is not guaranteed or endorsed by the publisher.

This work is licensed under a Creative Commons Attribution-NonCommercial 4.0 International License (CC BY-NC 4.0).