

Anamnestic, clinical, and dermoscopic predictors of malignancy in melanocytic lesions with peripheral globules: a retrospective study

Enrico Zelin,¹ Vanessa Mazzeletti,¹ Jessica Paladin,² Andrea Corio,³ Raffaele Dante Caposiena Caro,³ Giulia Bazzacco,^{1,3} Enzo Errichetti,⁴ Nicola Di Meo,³ Iris Zalaudek³

¹Institute of Dermatology, Santa Maria della Misericordia University Hospital, Udine; ²Department of Medicine, Surgery, and Health Sciences, University of Trieste; ³Dermatology Clinic, Hospital Maggiore, University of Trieste; ⁴Institute of Dermatology, Department of Medicine, University of Udine, Italy

Abstract

Melanocytic lesions with peripheral globules (MLPGs) usually represent lesions in an active growth phase and should be carefully evaluated in adults and the elderly, since melanoma can rarely present with this pattern. The primary aim of this study was to identify anamnestic, clinical, and dermoscopic features associated with malignancy (histologic outcome of melanoma) in MLPGs. The secondary aim was to describe the frequency of these features. We conducted a retrospective cross-sectional observational study, evaluating anamnestic, clinical, and dermoscopic features of MLPGs excised at the Dermatology Clinic of Trieste, Italy (January 2019–June 2023). The association between each variable and the histologic outcome (nevus or melanoma) was assessed using Fisher's exact test. Differences in age and lesion diameter distribution between nevi and melanomas were analyzed using Student's *t*-test for independent variables. Several lesion characteristics were associated with malignancy, including a personal history of melanoma ($p=0.0069$), localization on the lower limbs ($p=0.0215$), and lesion diameter ≥ 6 mm ($p=0.0025$). Several dermoscopic features were also associated with malignancy, namely non-circumferential peripheral globules (PGs; $p=0.0406$), regression ($p=0.0042$), evident vascular pattern/pink areas ($p=0.0007$), inverse network ($p=0.0243$), and asymmetric central globules ($p=0.0057$). Additionally, the comparison between melanoma and nevi groups confirmed that malignant lesions were characterized by a higher mean age at diagnosis ($p=0.0237$) and a larger mean diameter ($p=0.000112$). This study provides practical guidance for the management of MLPGs, highlighting that several anamnestic, clinical, and dermoscopic features are suggestive of malignancy.

Key words: melanocytic lesions; peripheral globules; dermoscopy.

Correspondence: Enrico Zelin, MD, Institute of Dermatology, Santa Maria della Misericordia University Hospital, 33100, Udine, Italy.
E-mail: enrico.zelin@gmail.com

Introduction

Melanocytic lesions with peripheral globules (MLPGs) usually represent lesions in an active growth phase, with a 28-fold probability of enlargement, and an average horizontal growth rate of 0.16–0.25 mm²/month.^{1–3} MLPGs are common in children and adolescents, typically representing “growing nevi”, but they should be carefully evaluated, especially in adults and the elderly, since melanoma can rarely present a pattern of peripheral globules (PGs).^{4,5} MLPGs management is often based on age group, but there is a lack of recommendations that consider anamnestic, clinical, and dermoscopic features.

Materials and Methods

We conducted a retrospective cross-sectional monocentric observational study evaluating anamnestic, clinical, and dermoscopic features of MLPGs excised at the Dermatology Clinic of

Trieste, Italy. The study was conducted in accordance with the ethical principles of the Declaration of Helsinki and was approved by the Trieste University Board (n.137/22.01.24).

The inclusion criteria were: i) documentation of at least one MLPG excised between January 2019 and June 2023, histologically confirmed as melanoma or nevus; ii) patient age ≥ 18 years; iii) adequate quality dermoscopic images; iv) presence of informed consent for data collection. The exclusion criteria were: i) MLPG excision not performed (resulting in the absence of a histological report); ii) patient age < 18 years; iii) absence of informed consent for data collection.

In case of patients with multiple lesions, anamnestic and clinical features were recorded separately for each lesion and categorized accordingly (nevi or melanoma group). Anamnestic data were obtained from the hospital platform, whereas clinical and dermoscopic features were evaluated by two independent experts (EZ and JP), blinded to the clinical outcome and histopathological diagnosis. Any disagreement was resolved through discussion. The recorded characteristics (Table 1) were divided into anamnestic (personal history of melanoma, family history of melanoma, pres-

ence of dysplastic nevus syndrome, or more than 100 nevi), clinical (age, gender, lesion location, lesion diameter, presence of a single or multiple MLPGs), and dermoscopic features (polymorphism of PGs, double row of PGs, non-circumferential PGs considered as distribution in <25% of the circumference, asymmetry of the core, regression, evident vascular pattern and/or pink areas, other features such as inverse network, white streaks, asymmetric central globules, central blotch, blue or black areas, polygons). All the recorded data were collected using Microsoft Excel 365 (Microsoft Corporation, Redmond, Washington, US).

Statistical analysis

Qualitative variables were described using absolute and relative frequencies, while for quantitative variables, mean, median, standard deviation (SD), and range were reported. The association between each variable and the histologic outcome (nevus or melanoma) was evaluated using Fisher's exact test, while differ-

ences in age and lesion diameter between nevi and melanomas were evaluated using Student's *t*-test for independent variables. The level of statistical significance was set to 5% ($p=0.05$). Statistical analyses were performed using R software 4.4.0 (R Foundation for Statistical Computing, Vienna, Austria, EU).

Results

A total of 105 lesions from 96 patients were included after the selection process based on the aforementioned inclusion and exclusion criteria.

Population features

Among the 96 patients, 89 (92.7%) presented a single MLPG, 5 patients (5.2%) had two lesions, and 2 patients (2.1%) had three

Table 1. Features of MLPGs recorded in the study: anamnestic, clinical, and dermoscopic characteristics and histological outcome.

Anamnestic features	Personal history of melanoma Familiar history of melanoma (first-degree relatives) Dysplastic nevus syndrome or nevi count >100
Clinical features	Age (years) Gender (M/F) Lesion anatomical location (head-neck region, thoracic region, abdomen, back, upper limbs, lower limbs, hands, feet) Lesion diameter (mm) Number of MLPGs in the same patient (in the study time interval)
Dermoscopic features	Polymorphism of PGs (presence of globules with different form, color, dimension, disposition) Double row of PGs Non-circumferential PGs (distributed on less than 25% of the lesion circumference) Core asymmetry Regression Evident vascular pattern and/or pink areas Other suspicious dermoscopic features (inverse network, white streaks, asymmetric central globules, central blotch, blue and black areas, polygons).
Histological outcome	Nevus/melanoma

MLPGs, melanocytic lesions with peripheral globules; PGs, peripheral globules.

Table 2. Anamnestic and clinical features of the study population (n=96).

	Patients, n (%)
Personal history of melanoma	
Present	43 (44.8)
Absent	53 (55.2)
Familiar history of melanoma	
Present	20 (20.8)
Absent	76 (79.2)
Dysplastic nevus syndrome or nevi count >100	
Present	22 (22.9)
Absent	74 (77.1)
Age	
Mean \pm SD (years)	50.3 \pm 15.0
Median (range) in years	49 (20-93)
Gender, n (%)	
Male	49 (51.0)
Female	47 (49.0)
Number of MLPGs excised	
Single lesion	89 (92.7)
Two lesions	5 (5.2)
Three lesions	2 (2.1)

SD, standard deviation; MLPGs, melanocytic lesions with peripheral globules.

lesions. Forty-nine patients (51%) were male, and 47 were female (49%), with a mean age of 50.3 years (SD 15.0, median 49, range 20-93). Among males, the mean age was slightly higher (52.3 years, SD 15.8, range 22-83) compared to the female group (48.2 years, SD 14.1, range 20-93). Considering the anamnestic data, 20.8% of the population (20/96) had a positive family history of melanoma, while almost half of the patients (44.8%, 43/96) had a personal history of previous melanoma. For 22.9% of patients (22/96), the presence of dysplastic nevus syndrome or more than 100 nevi on physical examination was reported. All data are summarized in Table 2.

Anamnestic, clinical, and dermoscopic features of the lesions

Among the 105 MLPGs, 92 were identified as nevi (87.6%) and 13 as melanomas (12.4%), based on the histology report. In case of lesions obtained from the same patient, anamnestic and clinical characteristics were repeatedly reported in their respective groups (nevi group or melanoma group) once for each lesion.

As far as concerns anamnestic data, in the malignant lesions category, there was a clear prevalence of a positive personal history of previous melanoma (85.6%, 11/13), with a statistically significant

difference compared to the nevi group (p=0.0069). Family history of melanoma was present in 21.7% of nevi and 15.4% of melanomas (p=0.7317), while dysplastic nevus syndrome or a nevus count >100 was reported in 25.0% of nevi and 15.4% of melanomas (p=0.7288).

Regarding clinical data, the male gender was the most represented in the cohort, also prevailing in the nevi category. Conversely, in the melanoma group, the female gender was slightly predominant, but no statistically significant difference was found (p=0.7716). The average age at diagnosis for all lesions was 50.4±14.8 years, being lower in the nevi category (49.2±14.4) compared to melanomas (59.0±14.6), with statistical significance (p=0.0237). However, after dichotomizing the data according to three different age cutoffs, no statistically significant threshold was found (age ≥40 years: p=0.0663; age ≥55 years: p=0.119; and age ≥65 years: p=0.1398).

In general, MLPGs tended to occur most frequently on the abdomen (29.5%), back (27.6%), and lower limbs (20.0%). A similar trend was observed in the nevi category which indeed represented the most significant numerical group, where the abdomen (32.6%) and back (26.1%) were predominant. However, in the melanoma group, the most represented location was the lower limbs (46.2%), followed by the back (38.5%). No melanomas were

Table 3. Anamnestic and clinical features of MLPGs collected in the study, subdivided into nevi and melanomas, with statistical analysis.

	Lesions (n=105) n (%)	Nevi (n=92) n (%)	Melanomas (n=13) n (%)	p
Personal history of melanoma				
Present	51 (48.6)	40 (43.5)	11 (84.6)	0.0069
Absent	54 (51.4)	52 (56.5)	2 (15.4)	
Familiar history of melanoma				
Present	22 (21.0)	20 (21.7)	2 (15.4)	0.7317
Absent	83 (79.0)	72 (78.3)	11 (84.6)	
Dysplastic nevus syndrome or nevi count >100				
Present	25 (23.8)	23 (25.0)	2 (15.4)	0.7288
Absent	80 (79.2)	69 (75.0)	11 (84.6)	
Age				
Mean ± SD in years	50.4±14.8	49.2±14.4	59.0±14.6	0.0237
Median (range) in years	48 (20-93)	48 (20-93)	61 (40-83)	
≥40 years	84 (80.0)	71 (77.2)	13 (100)	0.0663
≥55 years	35 (33.3)	28 (30.4)	7 (53.8)	0.119
≥65 years	17 (16.2)	12 (13.0)	5 (38.5)	0.1398
Gender				
Male	54 (51.4)	48 (52.2)	6 (46.2)	0.7716
Female	51 (48.6)	44 (47.9)	7 (53.8)	
Lesion anatomical location				
Upper limbs	9 (8.6)	9 (9.8)	0	0.5973
Lower limbs (without feet)	21 (20.0)	15 (16.3)	6 (46.2)	
Feet	2 (1.9)	2 (2.2)	0	1
Chest	12 (11.4)	11 (12.0)	1 (7.7)	1
Abdomen	31 (29.5)	30 (32.6)	1 (7.7)	0.1021
Back	29 (27.6)	24 (26.1)	5 (38.5)	0.3413
Neck	1 (1.0)	1 (1.1)	0	1
Lesion diameter				
Mean ± SD in mm	5.2±2.7	4.8±2.3	7.8±3.4	0.000112
Median (range) in mm	4 (2-15)	4 (2-15)	7 (3-15)	
≥6 mm	32 (30.5)	23 (25.0)	9 (69.2)	0.0025
Number of MLPGs excised				
Single lesion	89 (84.8)	80 (87.0)	9 (69.2)	0.1094
Two or more lesions	16 (15.2)	12 (13.0)	4 (30.8)	

SD, standard deviation; MLPGs, melanocytic lesions with peripheral globules; bold = p<0.05.

found on the upper limbs, feet, or neck. Localization on the lower limbs (excluding feet) was statistically associated with a diagnosis of melanoma ($p=0.0215$), unlike other sites.

The average diameter of the 105 lesions was 5.2 ± 2.7 mm (range 2–15 mm). Melanomas tended to have a larger diameter (7.8 ± 3.4 mm) compared to nevi (4.8 ± 2.3 mm, $p=0.000112$). The percentage of malignant lesions exceeding the dimensional cut-off of 6 mm was significantly higher compared to the nevi group (69.2% vs. 25.0%, $p=0.0025$).

Regarding the last clinical feature (number of excised MLPGs), the predominant tendency was to be single lesions for both categories (87.0% nevi and 69.2% melanomas, $p=0.1094$). Anamnestic and clinical data are summarized in Table 3.

Considering the dermoscopic features, polymorphism of PGs was a frequently observed characteristic in MLPGs (61.0% in total; 62.0% nevi and 53.8% melanomas), together with double row of globules, and asymmetry of the central core. Although these features are traditionally considered suspicious signs in the litera-

ture, they were actually well represented in both groups, with a tendency towards a higher presence in the cohort of malignant lesions for double row of PGs (38.5% melanomas vs. 28.3% nevi) and asymmetry of the core (61.5% melanomas vs. 42.4% nevi), not reaching statistical significance (Table 4).

On the other hand, a non-circumferential arrangement of PGs (<25% of the circumference), presence of regression, and evident vascular pattern/pink areas were statistically associated with the outcome of malignancy. Non-circumferential arrangement of globules was reported in 30.8% of melanomas vs. 8.7% of nevi ($p=0.0406$). Regression was observed in 7/105 lesions (6.7%), in particular in 30.8% of melanomas vs. 3.3% of nevi ($p=0.0042$). Evident vascular pattern/pink areas were treated as a single criterion since they typically coexisted within the same lesion and shared the same histological significance of vascularization and neoangiogenesis. These features were observed in 12/105 lesions (11.4%), particularly in 46.2% melanomas vs. 6.5% nevi ($p=0.0007$).

In addition to the aforementioned dermoscopic features, some

Table 4. Dermoscopy features of MLPGs collected in the study, subdivided into nevi and melanomas, with statistical analysis.

	Lesions (n=105) n (%)	Nevi (n=92) n (%)	Melanomas (n=13) n (%)	p
Polymorphism of PGs				
Present	64 (61.0)	57 (62.0)	7 (53.8)	0.7624
Absent	41 (39.0)	35 (38.0)	6 (46.2)	
Double row of PGs				
Present	31 (29.5)	26 (28.3)	5 (38.5)	0.5196
Absent	74 (70.5)	66 (71.7)	8 (61.5)	
Core asymmetry				
Present	47 (44.8)	39 (42.4)	8 (61.5)	0.2398
Absent	58 (55.2)	53 (57.6)	5 (38.5)	
Non circumferential PGs (<25% circumference)				
Present	12 (11.4)	8 (8.7)	4 (30.8)	0.0406
Absent	93 (88.6)	84 (91.3)	9 (69.2)	
Regression				
Present	7 (6.7)	3 (3.3)	4 (30.8)	0.0042
Absent	98 (93.3)	89 (96.7)	9 (69.2)	
Evident vascular pattern/pink areas				
Present	12 (11.4)	6 (6.5)	6 (46.2)	0.0007
Absent	93 (88.6)	86 (93.5)	7 (53.8)	
Inverse network				
Present	6 (5.7)	3 (3.3)	3 (23.1)	0.0243
Absent	99 (94.3)	89 (96.7)	10 (76.9)	
White streaks				
Present	2 (1.9)	1 (1.1)	1 (7.7)	0.2333
Absent	103 (98.1)	91 (98.9)	12 (92.3)	
Asymmetric central globules				
Present	4 (3.8)	1 (1.1)	3 (23.1)	0.0057
Absent	101 (96.2)	91 (98.9)	10 (76.9)	
Central blotch				
Present	2 (1.9)	1 (1.1)	1 (7.7)	0.2333
Absent	103 (98.1)	91 (98.9)	12 (92.3)	
Blue and black areas				
Present	2 (1.9)	2 (2.2)	0	1
Absent	103 (98.1)	90 (97.8)	13 (100)	
Polygons				
Present	1 (1.0)	1 (1.1)	0	1
Absent	104 (98.5)	91 (98.9)	13 (100)	

PGs, peripheral globules; bold = $p<0.05$.

rarer suspicious characteristics were also sought (inverse network, white streaks, asymmetric central globules, central blotch, blue and black areas, polygons) (Table 4). Only 15/105 lesions (14.3%) exhibited these characteristics, among which 7 were nevi (7/92; 7.6%) and 8 were melanomas (8/13; 61.5%). Of note, inverse network and asymmetric central globules were more represented in the melanoma category, with statistical significance (23.1% melanomas vs. 3.3% nevi, $p=0.0243$; 23.1% melanomas vs. 1.1% nevi, $p=0.0057$, respectively).

Summarizing the evaluated dermoscopic parameters, non-circumferential globules ($p=0.0406$), regression ($p=0.0042$), evident vascular pattern/pink areas ($p=0.0007$), inverse network ($p=0.0243$), and asymmetric central globules ($p=0.0057$) were statistically associated with melanoma. Dermoscopic data are summarized in Table 4, while a comparison of nevi and melanomas

with respect to the main dermoscopic features is represented in Figure 1.

Discussion

The primary objective of this study was to identify anamnestic, clinical, and dermoscopic criteria in MLPGs associated with a diagnosis of melanoma, and to report the frequency of these characteristics (secondary objective).

Our study confirmed statistical significance for several known risk factors for malignancy in MLPGs, as described in the literature.^{6,7} These factors included a personal history of melanoma ($p=0.0069$), localization on the lower limbs ($p=0.0215$), lesion diameter ≥ 6 mm ($p=0.0025$), and several dermoscopic features,

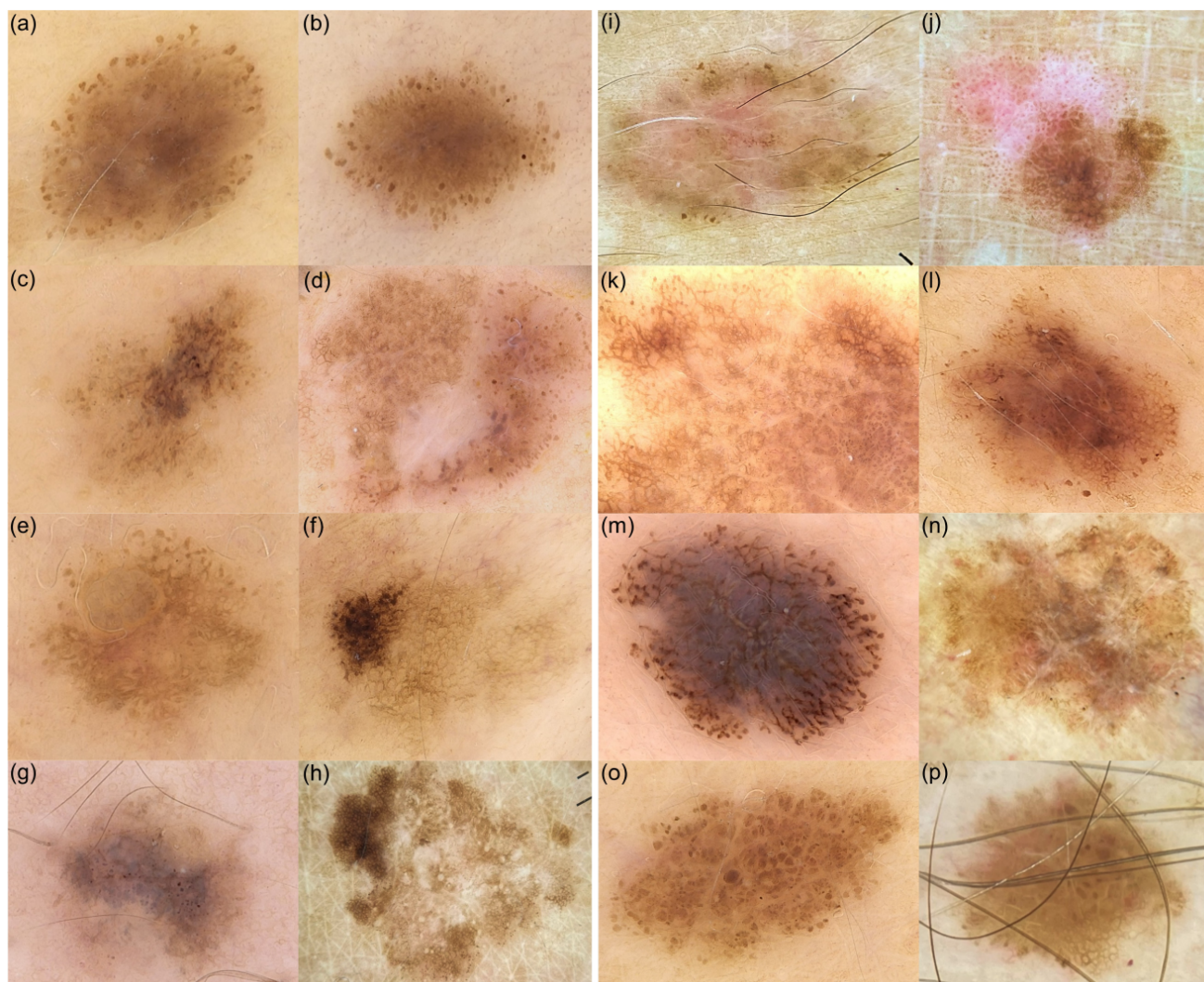


Figure 1. Comparison of nevi and melanomas on regard of the main dermoscopic features (10x magnification, polarized dermoscopy). Polymorphism of PGs in nevus (a) and melanoma (b); core asymmetry in nevus (c) and melanoma (d); of note, the melanoma also shows regression; non-circumferential PGs (<25% of the circumference) in nevus (e) and melanoma (f); regression in nevus (g) and melanoma (h); evident vascular pattern/pink areas in nevus (i) and melanoma (j); inverse network in nevus (k) and melanoma (l); white streaks in nevus (m) and melanoma (n); asymmetrical central globules in nevus (o) and melanoma (p).

namely non-circumferential PGs ($p=0.0406$), regression ($p=0.0042$), evident vascular pattern/pink areas ($p=0.0007$), inverse network ($p=0.0243$), and asymmetric central globules ($p=0.0057$). Furthermore, malignant lesions were characterized by a higher mean age at diagnosis ($p=0.0237$) and a larger mean diameter ($p=0.000112$).

Considering the anamnestic parameters, the only statistically significant feature was a personal history of melanoma, indeed representing a well-known major risk factor for developing a second melanocytic malignancy.^{6,7} For other considered anamnestic variables associated with increased melanoma risk according to literature data (family history of melanoma, presence of dysplastic nevi, total nevi count >100),^{6,7} the lack of association could be attributed to the sample selection and its limited size.

Regarding clinical criteria, male sex, identified in the literature as a melanoma risk factor,^{6,7} was not associated with malignancy in our study. On the other hand, the average age at diagnosis for malignant lesions (59.0 years) was distinctly higher than benign lesions (49.2 years), consistent with literature findings.⁸⁻¹⁰ However, it was not possible to establish a definitive threshold value for age as risk factor. Of note, in our cohort, the average age at diagnosis for benign MLPGs was higher than the one reported in the literature.⁴ This difference can be attributed to the enrolled population and the exclusion of minors from the study. Furthermore, according to the study inclusion criteria, each lesion had to be histologically confirmed and thus had to undergo excision, a procedure most commonly recommended for MLPGs in older patients.

When considering anatomical site, there was a clear prevalence of melanoma localization on the lower limbs, as reported by Reiter *et al.*⁸ On the other hand, no association was recorded with head-neck site,¹¹ which was, however, poorly represented in our sample. The association between melanoma and lower limbs is confirmed by the literature and could be justified by intermittent exposure to ultraviolet rays, one of the main environmental risk factors.^{6,7,12}

Regarding lesion size, our data confirmed that diameter is indeed one of the most relevant clinical diagnostic parameters of melanoma, which represents, by definition, a growing neoplasm.¹³ As cited in the literature, a lesion diameter ≥ 6 mm was predictive of malignancy.¹⁰ Conversely, nevi with PGs tended to have a smaller diameter (average diameter: 4.8 mm in nevi vs. 7.8 mm in melanomas, $p=0.000112$). Finally, considering the number of MLPGs on each patient, there was no statistically significant result, likely due to the difficulty in retrospective data collection. As for dermoscopic criteria, statistical significance was confirmed for several parameters considered as highly suspicious or melanoma-specific dermoscopic features in the literature, especially non-circumferential PGs, regression, evident vascular pattern/pink areas, inverse network, and asymmetric central globules. The presence of non-circumferential PGs (distributed on less than 25% of the lesion circumference), according to our data, as well as the literature, is a feature associated with malignancy.^{8,11} This is justifiable as lesions with areas of asymmetric growth are suspicious and more likely to be malignant.

Regarding the phenomenon of regression, it can occur in up to one-third of cases of primary cutaneous melanoma, presenting on dermoscopy as white scar-like areas with blue/gray dots, corresponding to fibrosis with the presence of melanophages.¹⁴ According to our data, 30.8% of malignant lesions exhibited this characteristic vs. only 3.3% of nevi. Pampin-Franco *et al.* reaffirmed the statistical association between regression structures and

melanoma with PGs, also suggesting a surgical approach to this type of lesion. Considering that MLPGs are by definition growing, the coexistence of simultaneous regression is strongly associated with malignancy, being an epiphenomenon of disorganized lesion development.¹⁰ Our study found an association between evident vascular patterns/pink areas and malignancy, which is also reported in the literature.^{9,10} These red-pink dermoscopic areas correspond histologically to irregular vascular development, representing a process of neoangiogenesis, indicative of the growth and invasive progression.^{15,16}

Furthermore, our study revealed that two other dermoscopic characteristics are suggestive of malignancy, namely inverse network and asymmetric central globules. Both are traditionally included in the group of suspicious diagnostic criteria for melanoma.^{17,18} The inverse network is characterized by a light-colored mesh surrounding darker (usually brown) central areas and can be associated with melanoma, Spitz nevi, dysplastic nevi, and growing nevi.¹⁹ While previous studies on melanocytic lesions with PGs did not find a statistically significant association with malignancy,⁸⁻¹⁰ our study introduces this new predictive aspect.

Regarding asymmetric central globules, according to a study by Jin Xu *et al.*, the presence of a cluster of such dermoscopic structures (*i.e.*, three or more globules arranged in a non-peripheral position within a melanocytic lesion) is associated with melanoma.²⁰ Also, studies by Pampin-Franco¹⁰ and Moraes⁹ found that dots and asymmetric globules within the MLPGs were associated with malignancy, consistently with our findings.

The other evaluated dermoscopic criteria, traditionally indicated as suspicious by the literature (polymorphism of PGs, double row of PGs, core asymmetry),^{8-10,20} did not demonstrate statistical significance, likely due to sample selection and its limited size. However, it should be noted that malignant lesions tended to exhibit these characteristics more frequently than nevi (except for polymorphism of PGs, which was slightly more represented in benign lesions according to our data).

Finally, regarding other rarely represented dermoscopic criteria (white streaks, central blotch, blue and black areas, polygons), data are insufficient to make meaningful epidemiological evaluations, as these characteristics were present in an extremely small number of lesions.

The main limitations of the study lie in its retrospective nature and the characteristics of the examined group, which may not be representative of the general population, due to the limited sample size and the presence of risk factors. Indeed, most patients included in this study were already under follow-up for a previous melanoma diagnosis or the presence of atypical lesions. In addition, based on the inclusion criteria, only histologically examined lesions were included. This indicates that the dermatologist deemed the considered MLPGs suspicious enough to warrant surgical excision.

Conclusions

PGs in melanocytic lesions are a dermoscopic sign of growth and can also be indicative of malignancy. Therefore, when considering MLPGs, it is important to recognize anamnestic, clinical, and dermoscopic criteria that allow for proper management, particularly favoring the excision of suspicious lesions and reserving conservative management for low-risk lesions.

Firstly, it is necessary to emphasize that, in the overall epidemiological evaluation of the study cohort, the majority of

MLPGs are nevi, as also indicated by literature data.^{2,9} Nonetheless, the analysis of clinical-anamnestic data and a careful dermoscopic evaluation are fundamental to identifying suspicious lesions. The presence of even a single suspicious characteristic should direct towards surgical excision with histological examination of the lesion. In summary, several factors were associated with an increased risk of malignancy in MLPGs, including a personal history of melanoma, localization on the lower limbs, diameter ≥ 6 mm, and the following dermoscopic criteria: non-circumferential PGs (<25% of the circumference), areas of regression, evident vascular pattern/pink areas, inverse network, and asymmetric central globules. Furthermore, characteristics such as advanced age, lesion asymmetry, and a double-row distribution of globules should be considered, as they can be suggestive of malignancy.

In conclusion, this study provides practical guidance for the evaluation and treatment of melanocytic lesions with PGs. Recognizing and appropriately managing these lesions can significantly improve patient outcomes by ensuring timely and accurate diagnosis of malignancies.

References

- Lazaridou E, Fotiadou C, Apalla Z. Melanocytic lesions with peripheral globules: still a pitfall in the differential diagnosis of melanoma. *J Eur Acad Dermatology Venereol* 2021;35:1040.
- Bajaj S, Dusza SW, Marchetti MA, et al. Growth-Curve Modeling of Nevi With a Peripheral Globular Pattern. *JAMA Dermatology* 2015;151:1338.
- Ilut PA, Camela E, Lallas K, et al. The Natural Evolution of Nevi with Peripheral Globules. *Dermatology* 2023:1-8.
- Zalaudek I, Schmid K, Marghoob AA, et al. Frequency of Dermoscopic Nevus Subtypes by Age and Body Site. *Arch Dermatol* 2011;147:663.
- Zalaudek I, Catricalà C, Moscarella E, Argenziano G. What dermoscopy tells us about nevocogenesis. *J Dermatol* 2011;38:16-24.
- Carr S, Smith C, Wernberg J. Epidemiology and Risk Factors of Melanoma. *Surg Clin North Am* 2020;100:1-12.
- Conforti C, Zalaudek I. Epidemiology and Risk Factors of Melanoma: A Review. *Dermatol Pract Concept* 2021:2021161S.
- Reiter O, Chousakos E, Kurtansky N, et al. Association between the dermoscopic morphology of peripheral globules and melanocytic lesion diagnosis. *J Eur Acad Dermatology Venereol* 2021;35:892-9.
- Moraes AFA, Blumetti TCMP, Pinto C, et al. Melanoma with peripheral globules: Clinical and dermoscopic features. *J Am Acad Dermatol* 2022;87:567-72.
- Pampin Franco A, Gamo Villegas R, Floristán Muruzábal U, et al. Melanocytic lesions with peripheral globules: results of an observational prospective study in 154 high-risk melanoma patients under digital dermoscopy follow-up evaluated with reflectance confocal microscopy. *J Eur Acad Dermatology Venereol* 2021;35:1133-42.
- Cappilli S, Ribero S, Cornacchia L, et al. Melanocytic Lesions With Peripheral Globules: Proposal Of An Integrated Management Algorithm. *Dermatol Pract Concept* 2023:e2023010.
- Raimondi S, Suppa M, Gandini S. Melanoma Epidemiology and Sun Exposure. *Acta Derm Venereol* 2020;100:adv00136.
- Rigel DS, Russak J, Friedman R. The Evolution of Melanoma Diagnosis: 25 Years Beyond the ABCDs. *CA Cancer J Clin* 2010;60:301-16.
- Ribero S, Moscarella E, Ferrara G, et al. Regression in cutaneous melanoma: a comprehensive review from diagnosis to prognosis. *J Eur Acad Dermatology Venereol* 2016;30:2030-7.
- Jour G, Ivan D, Aung PP. Angiogenesis in melanoma: an update with a focus on current targeted therapies. *J Clin Pathol* 2016;69:472-83.
- Russo T, Piccolo V, Ferrara G, et al. Dermoscopy pathology correlation in melanoma. *J Dermatol* 2017;44:507-14.
- Wolner ZJ, Yélamos O, Liopyris K, et al. Enhancing Skin Cancer Diagnosis with Dermoscopy. *Dermatol Clin* 2017;35:417-37.
- Neila J, Soyer HP. Key points in dermoscopy for diagnosis of melanomas, including difficult to diagnose melanomas, on the trunk and extremities. *J Dermatol* 2011;38:3-9.
- Pizzichetta MA, Talamini R, Marghoob AA, et al. Negative pigment network: An additional dermoscopic feature for the diagnosis of melanoma. *J Am Acad Dermatol* 2013;68:552-9.
- Xu J, Gupta K, Stoecker WV, et al. Analysis of Globule Types in Malignant Melanoma. *Arch Dermatol* 2009;145.

Received: 5 March 2025; Accepted: 18 May 2025.

Contributions: Enrico Zelin: study design, conceptualization, methodology, patient recruitment, database creation, writing, extraction of data; Vanessa Mazzeletti: manuscript review, patient recruitment; Jessica Paladin: methodology, database creation, writing, extraction of data; Andrea Corio, Raffaele Dante Caposiena Caro, Giulia Bazzacco: manuscript review; Enzo Errichetti, Nicola Di Meo, Iris Zalaudek: supervision. All authors have read and approved the final version of the manuscript.

Conflict of interest: the authors have no conflict of interest to declare.

Ethics approval and consent to participate: the study was reviewed and approved by the Trieste University Board (n.137/22.01.24). All included patients have given written informed consent to participate in this study.

Availability of data and materials: data supporting the findings of this study are available from the corresponding author upon reasonable request.

Publisher's note: all claims expressed in this article are solely those of the authors and do not necessarily represent those of their affiliated organizations, or those of the publisher, the editors and the reviewers. Any product that may be evaluated in this article or claim that may be made by its manufacturer is not guaranteed or endorsed by the publisher.

This work is licensed under a Creative Commons Attribution-NonCommercial 4.0 International License (CC BY-NC 4.0).