

Facial skin rejuvenation through plasma radiofrequency ablation combined with 5% resorcinol cream: clinical and line-field confocal optical coherence tomography evaluation

Caterina Mariarosaria Giorgio,¹ Gaetano Licata,² Eugenia Veronica Di Brizzi,¹ Graziella Babino,³ Elisabetta Fulgione,¹ Elvira Moscarella,¹ Giuseppe Lodi,¹ Nicola Maria Giorgio,¹ Vittorio Tancredi,¹ Giuseppe Argenziano,¹ Adone Baroni¹

¹Dermatology Unit, University of Campania, Naples; ²Dermatology Unit, San Antonio Abate Hospital, Trapani; ³Dermatology Unit, Department of Health Sciences, University of Basilicata, Potenza, Italy

Abstract

Skin aging is characterized by loss of elasticity, wrinkles, and textural changes. Treatments range from non-invasive options, such as alpha-hydroxy acids and retinoic acid, to invasive procedures like chemical peels and laser therapies. Plasma radiofrequency (PRF) offers a minimally invasive solution with a favorable balance of efficacy and tolerability. This study assessed the clinical and microscopic outcomes of combining PRF ablation with a galenic cream containing 5% resorcinol in Nourivan™

Antiox for facial skin aging. Forty-one patients with visible signs of aging underwent a single PRF session followed by weekly applications of a 5% resorcinol cream for six weeks. Outcomes were evaluated using digital photography and line-field confocal optical coherence tomography (LC-OCT) at baseline, three months, and six months. Primary endpoints included wrinkle reduction and texture improvement; secondary endpoints included adverse effects and patient satisfaction. At six months, 92% of patients showed significant wrinkle reduction and improved collagen organization in LC-OCT images. Skin texture improvements were reported by 85% of patients. Adverse effects, such as mild erythema and peeling, were transient and resolved without discontinuation. PRF ablation combined with 5% resorcinol cream is an effective and well-tolerated treatment for facial skin aging, offering significant improvements in skin texture and appearance. Further research is needed to confirm these findings and explore long-term effects.

Correspondence: Caterina Mariarosaria Giorgio, Dermatology Unit, University of Campania, Piazza Luigi Miraglia 2, 80138 Naples, Italy.

E-mail: caterinagiorgio80@gmail.com

Key words: facial skin rejuvenation; plasma radiofrequency; resorcinol; LC-OCT; aesthetic dermatology.

Conflict of interest: the authors have no conflict of interest to declare.

Ethics approval and consent to participate: institutional review board approval was not required for this study as only de-identified data were used in the analysis. Informed consent was obtained from the patients included in this study.

Consent for publication: the patients gave their written consent to use their personal data for the publication of this case report and any accompanying images.

Availability of data and materials: all data generated or analyzed during this study are included in this published article.

Received: 8 March 2025.

Accepted: 27 March 2025.

This work is licensed under a Creative Commons Attribution-NonCommercial 4.0 International License (CC BY-NC 4.0).

©Copyright: the Author(s), 2025

Licensee PAGEPress, Italy

Dermatology Reports 2025; 17:10342

doi:10.4081/dr.2025.10342

Publisher's note: all claims expressed in this article are solely those of the authors and do not necessarily represent those of their affiliated organizations, or those of the publisher, the editors and the reviewers. Any product that may be evaluated in this article or claim that may be made by its manufacturer is not guaranteed or endorsed by the publisher.

Introduction

Facial skin aging is mainly characterized by the loss of elasticity, the formation of wrinkles, and textural changes. In the field of aesthetic facial skin treatments, many therapeutic options can be taken into consideration, varying from superficial skin treatments, such as alpha-hydroxy acids, antioxidants, or retinoic acid, to more invasive procedures, such as dermabrasion, chemical peeling, or ablative laser treatments. Electro-medical equipment list for treatments targeting aging signs includes many energy- and light-based devices such as ablative lasers, non-ablative lasers, bipolar radiofrequency, fractionated radiofrequency, intensive pulsed light, *etc.*; among these, plasma radiofrequency (PRF) is considered one of the most versatile and tolerable techniques with an excellent invasiveness and result ratio.¹

PRF uses energy stimulated by the ionization of the atmospheric gas present between the device and the skin to stimulate tissue repair, collagen formation, and skin tightening.²⁻⁴ PRF technology generates a plasma spark that heats the dermal layers through the sublimation of the superficial layers of the skin, stimulating collagen remodeling, fibroblast activity, and neo-collagenesis, making it a valid approach for minimally invasive facial skin rejuvenation.¹⁻⁴

Resorcinol (m-dihydroxybenzene) is used in dermatology for many applications such as acne, hydradenitis, or for psoriasis topical preparations, acting through cytotoxicity and cytokine modulation and exerting keratolytic activities, so facilitating exfoliation, encouraging cellular turnover, and brightening the skin. Its action on the skin is known to improve texture and reduce fine lines.^{5,6} The inclusion of Nourivan™ Antiox in the galenic formulation enhances the bioavailability of resorcinol and its stability,

ensuring consistent therapeutic outcomes. This study investigates the outcomes of combining PRF ablation therapy with topical resorcinol to enhance facial skin rejuvenation.

Materials and Methods

This study reviewed 41 female patients (between 35 and 65 years old) with visible signs of skin aging (wrinkles, textural irregularity, dullness) who underwent a single session of PRF ablation (DAS, Technolux Srl, Milan, Italy), followed by weekly topical applications of a 5% resorcinol cream. All patients enrolled provided their informed consent forms before starting therapy. No contraindications to treatment, such as Fitzpatrick skin types V-VI, concomitant bacterial or viral infection, collagen vascular disorders, diabetes, malignancy, pregnancy, and ablative skin procedures carried out within the previous 6 months or history of hypersensitivity to resorcinol, were present. The skin areas to be treated were anesthetized with topical anesthetic cream (lidocaine) without occlusion for 40 minutes before starting treatment. The skin was superficially ablated with a single pass at 0.6 J energy and 3 Hz frequency with the detached spots technique of sublimation, leaving columns of intact epidermis. The treatment was followed by the application of a re-epithelializing cream twice daily for 10 days. Ten days after PRF ablation treatment, patients applied the 5% resorcinol cream weekly for 6 weeks, leaving it on the skin for two minutes before rinsing it off with physiological solution. The cream was formulated with Nourivan™ Antiox, a delivery system known for its antioxidant properties and skin-nourishing effects. The treatment areas included both sun-exposed (extrinsic aging) and sun-protected (intrinsic aging) regions, ensuring a comprehensive evaluation of aging patterns. The maximum treated area did not exceed 10 cm² per session to minimize potential systemic absorption and associated risks.

Results

All 41 patients completed the study. The primary outcomes assessed were a reduction in wrinkle depth, improvement in skin texture, and improvement of skin radiance and youthfulness.

The assessments were made at baseline, three months, and six months after treatment using digital photography and line-field confocal optical coherence tomography (LC-OCT). At LC-OCT, we evaluated the structural characteristics of the dermis and epidermis before and after skin rejuvenation treatment with the combined plasma radiofrequency and a topical resorcinol protocol.

At baseline, LC-OCT images revealed typical signs of skin aging. The epidermis appeared thinner and less uniform, while significant changes were observed in the dermis, which appeared hyper-reflective, with fragmented fibers and an elastotic structure. Collagen fibers showed marked densification, resulting in a whitish color and heightened reflectivity within the dermis (Figure 1a). This hyper-reflective appearance indicated dense, disorganized collagen and elastin fibers, suggesting compromised structural integrity and elasticity.

At the six-month follow-up, 92% of patients (38 out of 41) showed a significant reduction in wrinkle depth, data corroborated by digital photography and LC-OCT.

LC-OCT images demonstrated substantial improvements in key indicators of skin aging within the dermis. The previously hyper-reflective dermal areas became less reflective, with a darker, more even appearance, signifying reduced densification and improved organization of collagen and elastin fibers (Figure 1b). This change in coloration and reflectivity indicated the absence of dense fiber clumping and fragmentation, showing a rejuvenated, more flexible dermal structure. Furthermore, the dermal-epidermal junction (DEJ) became more defined and slightly wavy, indicating improved resilience and firmness. In the epidermis, increased thickness and improved DEJ architecture signified an overall rejuvenation of skin structure (Figure 1b).

In addition to wrinkle reduction, 85% of patients (35 out of 41) reported a noticeable improvement in overall skin texture. The

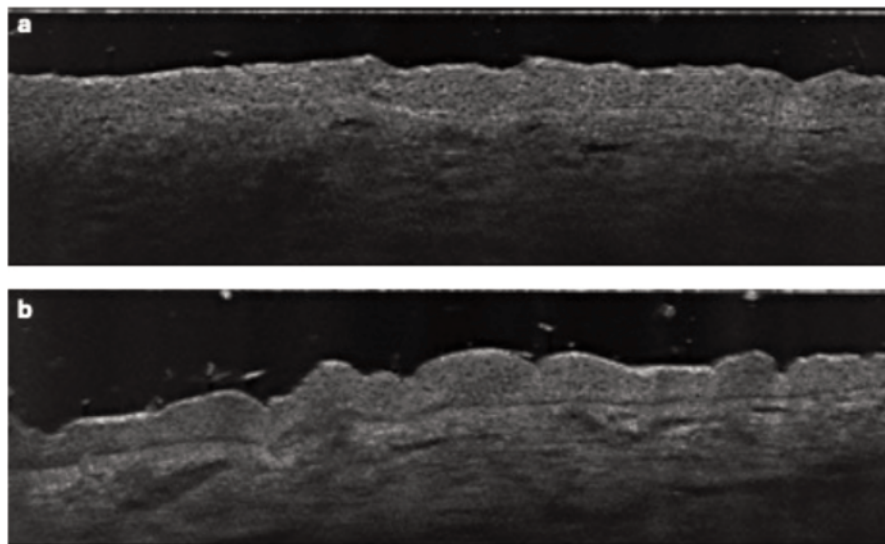


Figure 1. LC-OCT images. (a) At baseline, the dermis appears hyper-reflective with fragmented fibers and an elastotic structure; the epidermis is thin and irregular. (b) After six months following plasma radiofrequency ablation combined with topical application of 5% resorcinol cream, the dermis shows reduced reflectivity with a more organized arrangement of collagen and elastin fibers, accompanied by a thicker epidermis and a more defined dermal-epidermal junction.

skin appeared smoother and firmer, with an average reduction of fine lines. Patients also described a more uniform skin tone, with 72% (30 out of 41) noting reduced hyperpigmentation, particularly in sun-exposed areas. These results were validated by visual assessments with digital photography, which revealed a clear improvement in skin clarity and radiance (Figure 2).

We monitored for any adverse effects related to PRF ablation (e.g., erythema, edema) and 5% resorcinol cream (e.g., irritation, peeling) treatments during follow-up. Mild to moderate adverse effects were noted in a subset of patients. PRF ablation treatment was associated with moderate burnishing in all patients, which resolved in 5 days, with transient erythema in 34% of participants (14 out of 41), which resolved within 48 hours. Edema was reported in 18% of patients (7 out of 41), but this subsided within 24 to 48 hours post-treatment. No long-term complications from PRF treatment were observed. Resorcinol application was associated with mild irritation and transient peeling in 21% of patients (9 out of 41), particularly after the first two weekly applications. These effects were more pronounced in patients with sensitive skin but were managed effectively using a re-epithelializing cream. Symptoms resolved in all cases without requiring discontinuation of the treatment. No systemic side effects were reported, and no patient withdrew from the study due to adverse reactions. Importantly, in patients with a history of mild skin sensitivity, no severe or long-term complications were observed, indicating that the treatment protocol is well-tolerated even in more reactive skin types. While PRF ablation is generally well-tolerated, the addition of resorcinol raised some concerns regarding potential irritation. However, the formulation with Nourivan™ Antiox appears to have mitigated these effects, as most cases of irritation were mild and easily managed with standard moisturizers. The fact that no patients discontinued the study due to adverse effects highlights the overall tolerability of the treatments.

Furthermore, patient-reported outcomes were highly positive. A post-treatment questionnaire completed by all participants revealed that 95% of the cohort expressed satisfaction both with the treatment and with the obtained results. Specifically, 89% rated their skin as more radiant, while 92% felt their skin looked more youthful and rejuvenated.

Discussion

PRF therapy has long been established as a minimally invasive method for skin rejuvenation, specifically due to its ability to induce controlled dermal heating. The controlled dermal heating leads to collagen remodeling through fibroblast stimulation and increased dermal neocollagenesis, which are essential for reducing the depth of wrinkles and improving overall skin texture.^{1-4,7,8} The findings of this study further confirm the effectiveness of PRF ablation treatments in achieving these outcomes. However, the combination of PRF ablation treatment with topical resorcinol offers a new, synergistic approach that enhances the overall efficacy of the treatment.

The potential interaction between PRF and resorcinol remains to be fully elucidated. While PRF creates controlled zones of thermal damage that could enhance permeability, resorcinol application starts only after 10 days, limiting any immediate synergistic effect. It is possible that PRF-induced remodeling may create a skin environment that subsequently enhances the penetration of topicals, albeit in a delayed manner. Future studies should investigate the temporal relationship between PRF and resorcinol to confirm this hypothesis. Resorcinol, a keratolytic agent, works by breaking down the stratum corneum, accelerating the exfoliation of dead skin cells, and promoting cellular turnover.^{5,6} When applied after PRF treatment, resorcinol's keratolytic action is enhanced, leading to a more pronounced exfoliation and a brighter, smoother skin texture.

In addition to its keratolytic properties, resorcinol possesses anti-inflammatory and antioxidant effects, which help to reduce oxidative stress in the skin, a key factor in skin aging. The inclusion of Nourivan™ Antiox further amplifies this effect by providing a stable environment for resorcinol and adding its own antioxidant benefits. By mitigating the effects of environmental stressors such as UV radiation and pollution,^{5,6} this combination helps maintain skin integrity and delays further aging processes.

One of the key advantages of this combination therapy is its favorable safety profile. Most patients in this study experienced only mild and transient side effects, such as erythema and mild peeling, which resolved quickly without long-term complications.

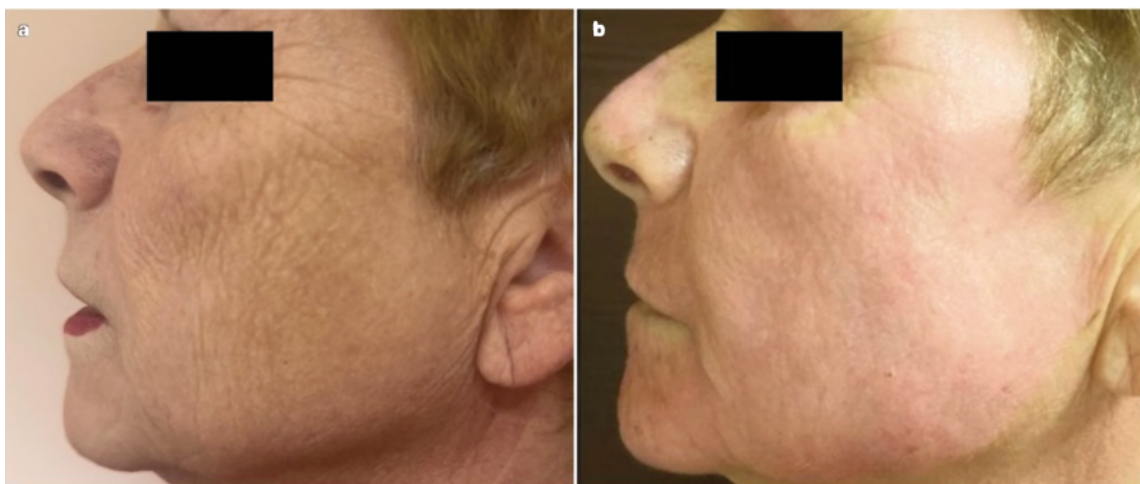


Figure 2. Clinical images. (a) At baseline, deep wrinkles, textural irregularities, and a dull skin tone are evident. (b) After 6 months following plasma radiofrequency ablation combined with topical application of 5% resorcinol cream, a significant reduction in wrinkle depth, smoother and more even skin texture, and an overall improvement in skin radiance and youthful appearance can be observed.

This suggests that the treatment is suitable for a wide range of skin types, including those with mild sensitivity or a history of intolerance to more aggressive treatments like deep chemical peels or ablative laser treatments. However, this study lacked a comparative design with parallel groups, which limits the ability to definitively attribute the observed effects to the combination therapy. Future research should include randomized controlled trials to confirm these findings.

Conclusions

The combination of PRF ablation and resorcinol represents a synergistic approach to skin rejuvenation. The inclusion of Nourivan™ Antiox in the resorcinol formulation also played a pivotal role. Its antioxidant properties not only stabilized the resorcinol but also helped in mitigating oxidative stress caused by environmental factors, which are known contributors to skin aging. The combination of PRF-induced collagen remodeling with resorcinol's exfoliative and anti-pigmentary effects created a synergistic approach that yielded sustained skin improvements over the six-month period. The results observed through LC-OCT highlight how the combined treatment promoted structural regeneration of the skin, reducing hyper-reflectivity and fiber fragmentation while restoring dermal elasticity and improving collagen organization. These enhancements in dermal microstructure confirm the effectiveness of the protocol in promoting skin rejuvenation and reducing visible signs of aging. However, it is important to acknowledge that LC-OCT is not widely available in routine clinical practice. Future studies should explore alternative imaging techniques, such as high-frequency ultrasound or reflectance confocal microscopy, to validate these findings in settings with limited access to LC-OCT.

The high patient satisfaction rates reflect not only the efficacy of the combined treatment but also its tolerability. In fact, the treatment was well-tolerated, with minimal and manageable side effects. Overall, the findings suggest that this combined treatment

could be an ideal solution for patients seeking a minimal-invasive approach to improve multiple signs of facial skin aging.

Further studies could explore optimizing the timing and dosage of resorcinol application and assess the long-term effects of repeated treatment cycles over several years. Additional research on the molecular mechanisms underlying the synergistic effects of PRF ablation and resorcinol could also provide further insights into the most effective facial skin rejuvenation strategies.

References

1. Di Brizzi EV, Russo T, Agozzino M, et al. Plasma radiofrequency ablation for treatment of benign skin lesions: Clinical and reflectance confocal microscopy outcomes. *Skin Res Technol* 2019;25:773-6.
2. Baroni A. Facial skin esthetic treatments with plasma radiofrequency ablation. *J Cosmet Dermatol* 2021;20:3934-9.
3. Bogle MA, Arndt KA, Dover JS. Evaluation of plasma skin regeneration technology in low-energy full-facial rejuvenation. *Arch Dermatol* 2007;143:168-74.
4. Foster KW, Moy RL, Fincher EF. Advances in plasma skin regeneration. *J Cosmet Dermatol* 2008;7:169-79.
5. Vachiramon V, Sakpuwadol N, Yongpisarn T, et al. Efficacy of isobutylamido thiazolyl resorcinol for prevention of laser-induced post-inflammatory hyperpigmentation: A randomized, controlled trial. *Cosmet Dermatol* 2024;23:2450-7.
6. Katoulis A, Efthymiou O, Liakou A, et al. Resorcinol 10% as a Promising Therapeutic Option for Mild Hidradenitis Suppurativa: A Prospective, Randomized, Open Study. *Skin Appendage Disord* 2023;9:438-43.
7. Baroni A. Non-surgical blepharoplasty with the novel plasma radiofrequency ablation technology. *Skin Res Technol* 2020;26:121-4.
8. Baroni A, Verolino P. Plasma Radiofrequency Ablation for Scar Treatment. *J Clin Med* 2021;11:140.