

Glomus tumor of the scrotum: an intraoperative differential diagnostic tip

Ahmed Nassar,^{1,2} Mohammed Alshahrani,² Ayed Alkahtani,² Adel Alfaifi,² Mothanna Najmi,² Ahmed Almutlaq,² Sulaiman Alfouzan,³ Mostafa Nassar,⁴ Esmat R. Eid²

¹Department of Dermatology and Venereology, Tanta University, Egypt; ²Department of Dermatology, The Armed Forces Hospitals-Southern Region, Khamis Mushayt, Aseer Province, Saudi Arabia; ³Division of Dermatology, Department of Medicine, King Abdulaziz Medical City, Riyadh, Saudi Arabia; ⁴Almabaraah Health Insurance Hospital, Tanta, Egypt

Abstract

Glomus tumors are rare, benign neoplasms arising from glomus bodies, primarily located in the subungual region and upper extremities, but uncommonly reported in areas such as the scrotum. Here, we describe a unique case of a glomus tumor of the scrotal skin in a 28-year-old male presenting with a two-year history of a painful, gradually enlarging scrotal nodule. Clinical examination revealed a tender oblong nodule, and dermoscopy suggested a benign neoplasm. Imaging and initial biopsy confirmed the lesion as a possible glomus tumor. Remarkably, during biopsy, the tumor spontaneously and completely “popped out”, narrowing the differential diagnosis to glomus tumor, angioliipoma, and epidermoid cyst. Histopathology confirmed the diagnosis of a glomus tumor, showing classic features including thick-walled blood vessels surrounded by smooth muscle actin-positive cells and a pseudocapsule. Postoperative pain resolution supported the clinical diagnosis. This case highlights the importance of considering glomus tumors in the differential diagnosis of painful scrotal lesions, especially when a mass exhibits spontaneous ejection during manipulation. To our knowledge, this is the first reported case of a scrotal glomus tumor in Saudi Arabia.

Key words: glomus; scrotum; benign neoplasm.

Correspondence: Ahmed Almutlaq, Department of Dermatology, The Armed Forces Hospitals-Southern Region (AFHSR), Khamis Mushayt, Aseer Province, Saudi Arabia. E-mail: Dr.ahmedmutlaq@gmail.com

Introduction

Glomus bodies, found primarily near the surface of the skin in the extremities, are comprised of smooth muscle cells referred to as glomus cells and arteriovenous shunts. Their primary function involves regulating skin temperature.¹ Glomus bodies have the potential for hyperplasia with subsequent formation of glomus tumors.² These tumors are typically benign and are mostly diagnosed in the subungual region and upper extremities. However, they have been rarely reported in other areas such as the stomach lining, glans penis, and scrotum.^{1,3} They are thermosensitive and may present with paroxysmal pain.² Hereinafter, we describe an intraoperative differential diagnostic tip in a case of glomus tumor of the scrotal skin.

Case Report

A 28-year-old single Saudi male patient who was otherwise healthy presented with a painful lesion of the scrotal skin. The lesion started about two years before, and its size had increased very slowly; touch could elicit pain, but it was sometimes spontaneous. There was no history of previous trauma or disease of the scrotum, nor was there any history of medication taken before its appearance.

The family history was irrelevant. On examination, there was a right hemiscrotal oblong-shaped skin nodule with normal overlying skin. It measured about 12×5 mm. The pain was intolerable on palpating the lesion. Dermoscopy revealed a white, structureless area (Figure 1), which suggests a benign neoplasm vs. an epidermoid cyst. The differential diagnosis was broad and included leiomyoma, angioliipoma, glomus tumor, neural tumor, other painful tumors of the skin, and epidermoid cyst. Complete blood count and liver and renal functions showed no abnormalities. Ultrasound showed a small hypoechoic skin lesion measuring 11×4 mm, which suggested a neoplasm vs. an epidermal inclusion cyst. A lesional biopsy was performed. During the biopsy and while the skin below the lesion was squeezed between the left index and thumb fingers to control the bleeding, a red gelatinous mass popped out spontaneously and completely (Figure 2). In light of this observation, we limited and rearranged our differential diagnosis to include glomus tumor, angioliipoma, and epidermoid cyst. The patient reported the disappearance of pain after surgery and thereafter. Histopathology showed a mass of thick-walled blood vessels intimately surrounded by sheets of uniform, banal, round cells with round basophilic nuclei and eosinophilic cytoplasm (Figure 3). The mass was surrounded by a pseudocapsule. The cells were smooth muscle actin (SMA) positive and desmin negative. CD34 was expressed by the vascular endothelium, but not by the perivascular cells. Ki67 proliferation index was about 1%, indicating the benignity of the tumor, and p63 was neg-

ative, denoting no squamous or myoepithelial cell origin. Clinicopathologically, the diagnosis was a glomus tumor of the scrotum.

Discussion

The diagnosis of glomus tumor is mainly clinical and depends on the presence of the classical triad of symptoms, including severe paroxysmal pain, pinpoint pain, and cold sensitivity,⁴ and the clinical presentation (including dermoscopy) in addition to three useful clinical findings (especially for glomus tumors in the nail bed). These tests rely on eliciting pain, such as Love's pin and cold sensitivity tests, or reducing pain and tenderness, such as Hildreth's tourniquet sign. Reducing or omitting the pain by repeating Love's pin test together with the tourniquet indicates a

positive result. On the other hand, tourniquet removal followed by sudden recurrence of pain also indicates a positive result.^{5,6}

In the current case, spontaneous and complete popping out of the tumoral mass helped shorten the differential diagnosis to glomus tumor, angioliipoma, and epidermoid cyst. The paroxysmal pain, together with the intraoperative appearance of the popped-out mass, could direct the dermatologist to consider a glomus tumor as the first possibility in the differential diagnosis. A possible explanation for this finding is that glomus tumors are mostly surrounded by thin pseudocapsules⁷⁻¹⁰ and are possibly connected by thin stalks/cords of tissue to the surrounding tissues, somewhat similar to the connection of the fetus to the placenta by the umbilical cord (Figure 4). These stalks/cords are easily disconnected by manipulation during biopsy. Of note, and to the best of our knowledge, this is the first case of glomus tumor of the scrotum reported from Saudi Arabia.

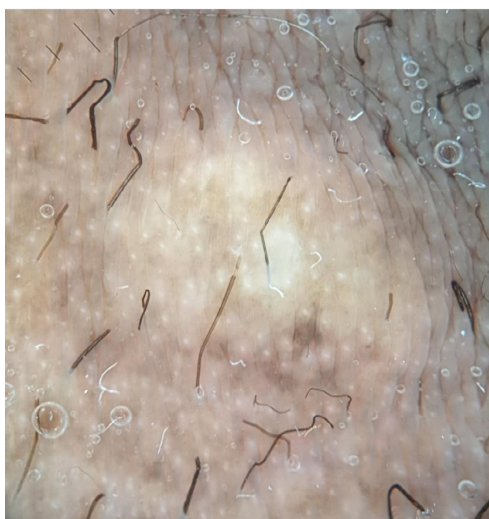


Figure 1. Dermoscopy of the lesion shows a white, structureless area.

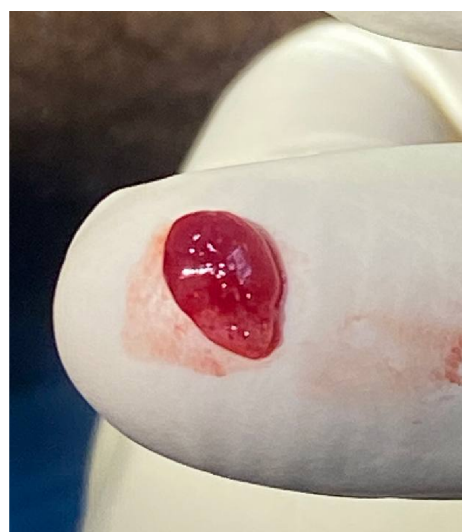

Figure 2. The red gelatinous tumoral mass that popped out spontaneously.

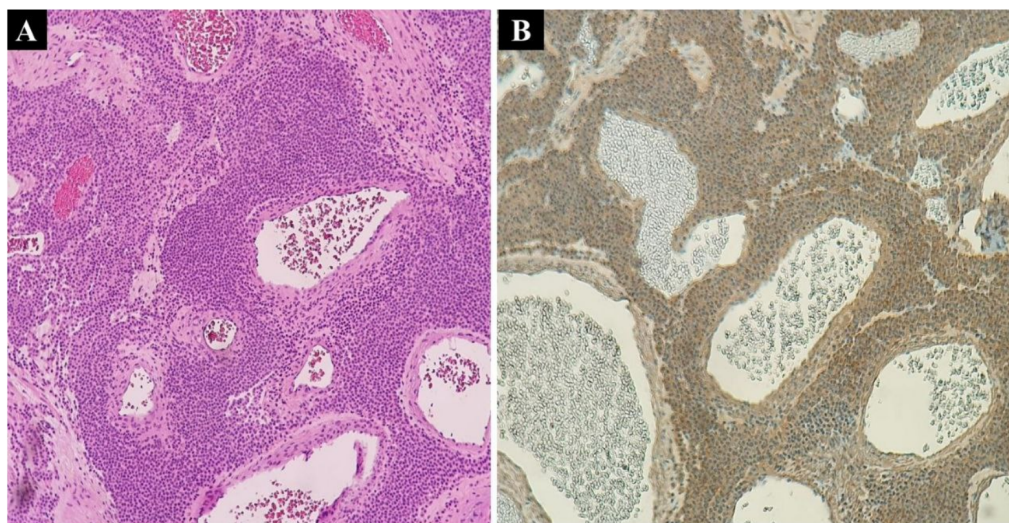


Figure 3. (A) Thick-walled blood vessels intimately surrounded by sheets of uniform, banal, round cells with round basophilic nuclei and eosinophilic cytoplasm; (B) positive SMA.

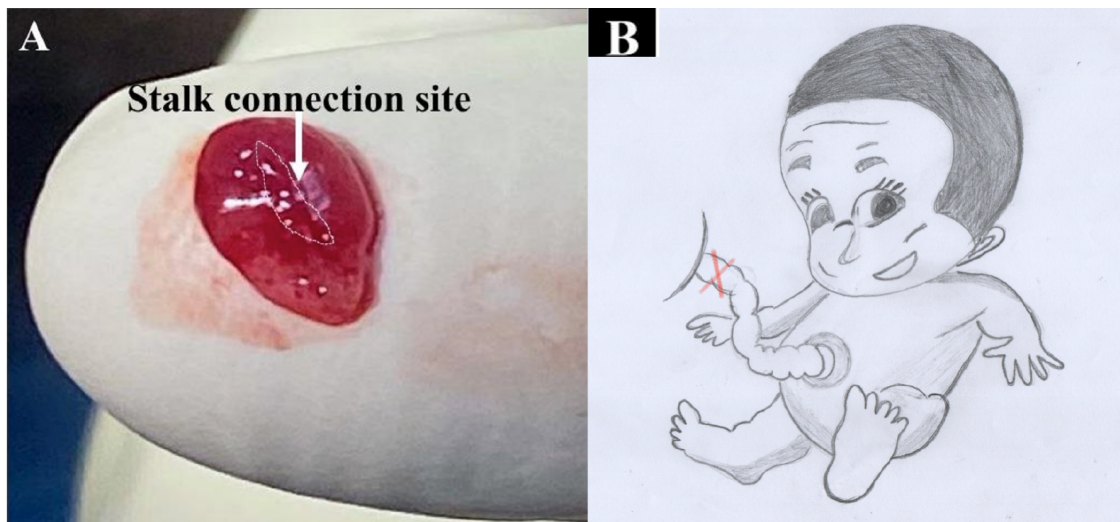


Figure 4. The stalk connects the mass to the surrounding tissues (A) in a way similar to the connection of the fetus to the placenta by the umbilical cord (B).

Conclusions

Glomus tumors of the scrotal skin are rare. Therefore, whenever a painful skin tumor appears spontaneously and completely during biopsy, a glomus tumor should be considered the primary possibility in the differential diagnosis.

References

- Gombos Z, Zhang PJ. Glomus tumor. Arch Pathol Lab Med 2008;132:1448-52.
- Lee W, Kwon SB, Cho SH, et al. Glomus tumor of the hand. Arch Plast Surg 2015;42:295-301.
- Miller JA, Moxon NR, Morency EG, et al. First presentation of a scrotal glomus tumor in an adolescent male: A case report. Urol Case Rep 2020;31:101175.
- Carroll RE, Berman AT. Glomus tumors of the hand: review of the literature and report on twenty-eight cases. J Bone Joint Surg Am 1972;54:691-703.
- Netscher DT, Aburto J, Koepplinger M. Subungual glomus tumor. J Hand Surg Am 2012;37:821-3; quiz 824.
- Tang CY, Tipoe T, Fung B. Where is the Lesion? Glomus Tumours of the Hand. Arch Plast Surg 2013;40:492-5.
- Stewart DR, Sloan JL, Yao L, et al. Diagnosis, management, and complications of glomus tumours of the digits in neurofibromatosis type 1. J Med Genet 2010;47:525-32.
- Chun JS, Hong R, Kim JA. Extradigital glomus tumor: A case report. Mol Clin Oncol 2014;2:237-9.
- Macharia C, Nthumba PM. Glomus tumor presenting as complex regional pain syndrome of the left upper limb: a case report. J Med Case Rep 2015;9:293.
- AlNuaim B, Binsulaiman N, Alkohlani, et al. Diagnosis of glomus tumor of the elbow: A case report. Int J Surg Case Rep 2022;90:106709.

Received: 11 March 2025; Accepted: 27 March 2025.

Conflict of interest: the authors declare no potential conflict of interest.

Ethics approval and consent to participate: no ethical committee approval was required for this case report by the Department, because this article does not contain any studies with human participants or animals. Informed consent was obtained from the patient included in this study.

Consent for publication: The patient gave his written consent to use his personal data for the publication of this case report and any accompanying images.

Availability of data and materials: all data underlying the findings are fully available.

Acknowledgments: the authors wish to thank Dr. Robert J. Pariser, Professor of Dermatology and Dermatopathology at Eastern Virginia Medical School in Norfolk, VA, USA, for his valuable contributions in revising this work.

Publisher's note: all claims expressed in this article are solely those of the authors and do not necessarily represent those of their affiliated organizations, or those of the publisher, the editors and the reviewers. Any product that may be evaluated in this article or claim that may be made by its manufacturer is not guaranteed or endorsed by the publisher.

This work is licensed under a Creative Commons Attribution-NonCommercial 4.0 International License (CC BY-NC 4.0).